

**ERIC E. GOFNUNG CHIROPRACTIC CORP.**

*QME OF THE STATE OF CALIFORNIA*

***SPORTS MEDICINE & ORTHOPEDIC - NEUROLOGICAL REHABILITATION***

***6221 Wilshire Boulevard, Suite 604 • Los Angeles, CA 90048 • Tel: (323) 933-2444 • Fax: (323) 933-2909***

---

**PROOF OF SERVICE BY MAIL**

STATE OF CALIFORNIA, COUNTY OF LOS ANGELES

I am a resident of the County aforesaid: and I am over the age of eighteen years and not a party to the within action: my business address is 6221 Wilshire Boulevard, Suite 604 Los Angeles, CA 90048.

On 21 day of September 2021 I served the within concerning:

**Patient's Name:** Seeram, Sandra

**SIF Case:** SIF12217188

On the interested parties in said action, by placing a true copy thereof enclosed in a sealed envelope with postage thereon fully prepaid in Los Angeles, California, to be hand delivered Via United States Mail.

- |   |  |
|---|--|
| <input type="checkbox"/> MPN Request                                      | <input type="checkbox"/> QME Appointment Notification  |
| <input type="checkbox"/> Notice of Treating Physician                     | <input type="checkbox"/> Designation Of Primary Treating Physician   |
| <input type="checkbox"/> Medical Report _____                             | <input type="checkbox"/> Initial Comprehensive Report  |
| <input type="checkbox"/> Itemized – ( Billing ) / HFCA<br><u>8/8/2022</u> | <input type="checkbox"/> Re-Evaluation Report / Progress Report (PR-2)   |
| <input type="checkbox"/> Doctor’s First Report                            | <input checked="" type="checkbox"/> Subsequent Injury Benefits Trust Fund Medical<br>Evaluator’s ML-201 Report |
| <input type="checkbox"/> RFA  | <input type="checkbox"/> Permanent & Stationary  |
| <input type="checkbox"/> Financial Disclosure                             | <input type="checkbox"/> Authorization Request for Evaluation/Treatment<br><u>8/8/2022</u>                     |

List all parties to whom documents were mailed to:

cc: Workers Defenders Law Group  
Natalia Foley, Esq.  
8018 E. Santa Ana Cyn Suite 100-215  
Anaheim Hills, CA 92808

Subsequent Injury Benefits Trust Fund  
1750 Howe Avenue, Suite 370  
Sacramento, CA 95825  
Attn: Jeff Souza, WC Consultant

I declare under penalty and perjury under the laws of the State of California, that the foregoing is true and correct, and that this Declaration was executed at Los Angeles, California on 21 day of September 2022.



---

**Ilse Ponce**

# ERIC E. GOFNUNG CHIROPRACTIC CORP.

*SPORTS MEDICINE & ORTHOPEDIC - NEUROLOGICAL REHABILITATION*

*6221 Wilshire Boulevard, Suite 604 / Los Angeles, California 90048 / Tel. (323) 933-2444 / Fax (323) 933-2909*

---

August 08, 2022

Subsequent Injury Benefits Trust Fund  
1750 Howe Avenue, Suite 370  
Sacramento, CA 95825  
Attn: Jeff Souza, WC Consultant

Workers Defenders Law Group  
8018 E. Santa Ana Cyn., Ste. 100-215  
Anaheim Hills, CA 92808  
Attn: Natalia Foley, Esq.

Re: Patient: SEERAM, Sandra  
SSN: 105-68-8936  
EMP: JP Morgan Chase  
SIBTF: SIF12217188  
INS: **Prudential**  
Claim #: **12651526**  
Last EAMS #: ADJ12217188  
DOI (SIBTF INJURY): CT: 05/17/2018 - 05/18/2019

## **SUBSEQUENT INJURY BENEFITS TRUST FUND** **MEDICAL EVALUATOR'S ML-201 REPORT**

Dear Gentlepersons:

The above-named patient was seen for a Subsequent Injury Benefits Trust Fund Medical Evaluation for determining eligibility, pursuant to California Labor Code 4751 on August 08, 2022, in my office located at 6221 Wilshire Boulevard, Suite 604, Los Angeles, CA 90048. The information contained in this report is derived from a review of the available medical records, as well as the oral history as presented by the patient.

This report is billed under ML-201 pursuant to California Code of Regulations 9793(h), and 9795(b)(c).

- **ML-201-95 – This is a Comprehensive Medical-Legal Evaluation.**
- Number of pages of records reviewed in preparation of this report = 6263
- Total Billable MLPRR Units (Subtract 200 pages for MLPRR)= 6063

The evaluation is not intended to ascertain the applicant's current function as it relates to the above captioned industrial injury, but rather determine whether pre-existing disability in combination with impairments arising from the subsequent industrial injury meet the requirements that would qualify the injured worker for SIBTF benefits. The Subsequent Injury Benefits Trust Fund (SIBTF) liability deals with pre-existing impairment and/or pre-existing disability. In other words, disability which was present prior to the industrial injury noted above. In essence, we are looking into the past in order to determine to what extent the injured worker was disabled, at some time prior to the settled industrial injury noted above. In this report, we will discuss whether or not the injured worker had an industrial injury and whether or not there was an evidentiary basis to determine pre-existing permanent disability. Finally, we will determine whether or not the applicant preliminarily meets the initial criteria for SIBTF eligibility of 35% permanent disability, or 5% permanent disability to an opposite corresponding member, and whether or not he/she will likely incur a total disability in excess of 70%, subject to additional medical evaluations in various medical specialties.

A request was made by Workers Defenders Law Group for me to evaluate Ms. Sandra, to determine her qualification for the Subsequent Injury Benefits Trust Fund. This evaluation is being performed to address the applicant's pre-existing disability to various body parts, as well as outline additional impairment and disability arising from the injury occurring on a cumulative trauma basis from May 17, 2018 through May 18, 2019 to her eye, neck, upper extremities, back, shoulder(s), lower extremities, digestive system, respiratory system, skin (dermatitis, etc.), digestive system, and nervous system, which are the subsequent industrial injuries. I have been authorized to evaluate the industrial injuries and any pre-existing problems. I have been advised to order further evaluations as necessary from other specialists.

Upon meeting Ms. Seeram, I introduced myself and discussed with her my role as an evaluator in this SIBTF matter. She expressed no objection to proceeding with the evaluation.

**Initial SIBTF Summary:**

- 1. Did the worker have industrial injury? Yes.**
- 2. Did the industrial injury rate to 35% disability without modification for age and occupation? Yes.**
- 3. Did the worker have a preexisting labor disabling permanent disability? Unable to determine at this time.**
- 4. Did the preexisting disability affect an upper or lower extremity, or eye? – Unable to determine at this time. This patient requires an ophthalmology vs. optometry evaluation.**

**5. Did the industrial permanent disability affect the opposite and corresponding body part? Unable to determine at this time. This patient requires an ophthalmology vs. optometry evaluation.**

**6. Is the total disability equal to or greater than 70% after modification? Unable to determine, but total impairment is over 90% whole person.**

**7. Is the employee 100% disabled or unemployable from other preexisting disability and work duties together? Unable to determine at this time. I need to see the vocational rehabilitation specialist report.**

**8. Is the patient 100% disabled from the industrial injury? Unable to determine at this time. Please see #7 above.**

**10. Evaluation or diagnostics needed? Left Hip and wrist Xrays.**

**JOB DESCRIPTION (SUBSEQUENT INJURY) :**

Ms. Seeram was employed by JP Morgan Chase as a branch manager at the time of the injury. They began working for this employer on December 27, 1988. The patient worked full time.

Job activities included opening and closing the branch, unarming, doing cash audits, loading cash machines, driving to different branches, opening up tele-drawer throughout the day, covering lunches and employee call-outs, covering when the branch was short staffed, opening up new accounts, doing all supervisor overrides, attending meetings with employees and entire staff, hiring, terminating employees, customer services, handling customer complaints, covering different branches with no team, hanging up merchandise, take it down, change it out, searching her branch and other branches for outdated collateral, doing daily goals for each employee, daily reports to her employer, attending conference calls weekly, sales goals, responsible for every employee's production and numbers, (mystery shoppers for operations), and beating prior year's numbers, letting customers into the safety deposit boxes, helping employees get cash and coin throughout the day, ordering and chipping, opening and closing bank accounts, helping employee with sales, making sure they were on point with their sales calls, putting away boxes of supplies and merchandise as well as counting and putting away bags of money, pulling cartridges from the ATM machines and fill them with money as well as lobby management.

Re: Patient – SEERAM, Sandra  
Report Date – August 08, 2022  
Page 4

The physical requirements consisted of sitting, walking, standing, flexing, twisting, and side-bending and extending the neck, bending and twisting at the waist, squatting, climbing, and kneeling.

The patient is a right-hand dominant female, and she would use the bilateral upper extremities repetitively for simple grasping, power grasping, fine manipulation, keyboarding, writing, pushing, and pulling, reaching at shoulder level, reaching above shoulder level, and reaching below shoulder level.

The patient was required to lift and carry objects while at work. The patient was required to lift and carry objects weighing up to 50 pounds.

The patient worked 8-10 hours per day and five to six days a week. Her work hours varied. Lunch break was 30 minutes. Rest break was 10 minutes. She relates she did not take her breaks often. The job involved working 100% indoors.

The last day the patient worked for JP Morgan Chase was March 15, 2019.

There was no concurrent employment at the time of the injury.

The patient denies working for any new employer.

**Prior Work History:**

The patient worked for the above employer for 33 years

**HISTORY OF SUBSEQUENT INJURIES AND TREATMENT ACCORDING TO PATIENT:**

**CUMULATIVE TRAUMA: 05/17/2018-05/18/2019**

The patient states that while working at her usual and customary occupation as a branch manager for JP Morgan Chase, they sustained a work-related injury to her head, neck, both shoulders, both hands, both knees, upper back, gastrointestinal system, circulation system, nervous system, and psyche, which the patient developed in the course of employment due to continuous trauma dated April 28, 2011, to April 11, 2012. The patient worked in a stressful environment due to the excessive workload and demeaning comments from her superiors in front of her employees or customers. She was doing the job of assistant branch manager and branch manager. As a result, she developed anxiety, stress, depression, and insomnia. The patient attributes the injuries due to prolonged standing and repetitive movements, bending, stooping, forceful pushing, pulling, gripping, and grasping, while working on a computer with a right-handed mouse, and keyboarding, and signing papers continuously throughout her work day. She had to remove the cartridge from the ATM machines and the vault, lift the cartridge, put them together, and fill

Re: Patient – SEERAM, Sandra  
Report Date – August 08, 2022  
Page 5

them up multiple times per day. In 2009, she developed gradual onset of pain and discomfort. She reported the injury to her employer, but she was ignored, and she was not referred her for medical care.

In 2009, she sought medical care from her primary care physician. She was referred to physical medicine for therapy for her neck, shoulders, back and hands. From 2009 through March of 2022, she has remained under the care of Dr. Helen Chung, a physical medicine specialist, at Kaiser through her health insurance. Treatment has consisted of x-rays, MRI scans, physical therapy, acupuncture treatment, and prescribed medication.

In 2016, the patient was referred for pain management evaluation in Kaiser. Medication was prescribed. She underwent a series of three injections of trigger points to her upper back for pain. She last saw her pain management doctor in November of 2021.

In 2019, she sought an attorney and was referred to a Wellness Center in Long Beach to Dr. Iseke for her work comp case. Treatment included evaluation. She completed several sessions of physical therapy, acupuncture, and shockwave therapy for her neck as she recalls. She stopped medical care in early 2020 due to the pandemic and continued her care with Kaiser by zoom and telemedicine.

The patient came under the care of Psychiatrist Dr. Curtis in about 2019 and remained under his care for about 1 year through for the work comp case. She was also seen by another psychiatrist Dr. Gul Ebrahim.

The patient came under the care of Internist Dr. Daldalyan in about 2021 and remains under his care to present for the work comp case.

In June of 2021, she had a follow-up with Dr. Chung at Kaiser.

In July of 2021, she was referred to Dr. Freedman who is a pain specialist regarding spinal injection. Cervical epidurals are pending.

On August 3, 2021, the patient was evaluated by Daniel Davis PA for an orthopedic evaluation.

In September of 2021, she returned to Dr. Freedman for a follow about need for pain blocks.

In November of 2021, she was referred to a Dr. Langit-Cole, but patient is not sure of the specialty. She was advised on home exercises.

On March 25, 2022, she came under the care of Primary Care/Internist Dr. Clemence who has become her primary care physician at Kaiserf. He recommended acupuncture which is pending scheduling.

In April of 2022, the patient underwent x-rays were obtained.

Re: Patient – SEERAM, Sandra  
Report Date – August 08, 2022  
Page 6

On April 2, 2022, the patient was referred for an MRI scan of the cervical spine.

On April 18, 2022, the patient underwent x-rays.

She remains under the care of Dr. Clemence to the present.

The patient underwent an Orthopedic QME evaluation by Dr. Joanne Halbrecht in late 2020.

The patient underwent a Psychiatric PQME evaluation by Dr. Spencer as well.

In April of 2022, the patient underwent a QME evaluation by Dr. Stewart Lonky, an internist and pulmonary specialist.

On July 6, 2022, the patient was evaluated by Dr. Madonna Garcia, vocational rehabilitation counselor with MRC.

### **CURRENT COMPLAINTS:**

#### **Headaches**

Intermittent and moderate. She has difficulty concentrating.

#### **Neck:**

There is radiating pain from the neck into the shoulders, upper back and head, and they have been experiencing frequent headaches. She is experiencing numbness and tingling or burning sensations. The pain is moderate, and the symptoms occur intermittently to frequently in the neck. There is cracking and grinding of the neck with range of motion and twisting and turning the head and neck. The pain is aggravated with flexing or extending the head and neck, turning the head from side to side, prolonged positioning of the head and neck, forward bending, pushing, pulling, lifting, and carrying greater than 5 pounds, and working or reaching at or above shoulder level. The patient has difficulty falling asleep and is often awakened during the night by neck pain. There are stiffness and a restricted range of motion in the head and neck. The pain level varies throughout the day.

#### **Bilateral Shoulders/Arms:**

The pain radiates to the arms and hands. The pain is moderate, and the symptoms occur intermittently to frequently, in both shoulders. There is instability of the shoulders, as well as clicking and grinding sensations. Patient experiences weakness and restricted range of motion for the shoulders and numbness and tingling in the shoulders, arms, and hands. The numbness and tingling in the hands and fingers awaken the patient at night. Patient complains of stiffness and experiences increased pain with repetitive motion of the arms/shoulders. The pain is aggravated with backward, lateral, and overhead reaching, pushing, pulling, lifting, and carrying greater than 3-5 pounds, and repetitive use of the bilateral upper extremities. Pain level varies

throughout the day depending on activities. The patient is not able to sleep on the either shoulder due to the pain. The patient has difficulty falling asleep and awakens throughout the night due to the pain and discomfort.

### **Bilateral Hands/Wrists:**

The pain is moderate to severe, and the symptoms occur frequently in the right and left wrist, hand, and fingers, which is present all the time. The pain is aggravated with gripping, grasping, torquing motions, flexion, and extension of the wrists/hands, pinching, fine finger manipulation, driving, repetitive use of the left and right upper extremity, pushing, pulling, lifting, and carrying greater than 2-3 pounds. The patient has cramping, weakness, and loss of grip strength in hands and wrists and has dropped objects, as a result. There is tingling in the hands and fingers. Patient has difficulty sleeping and awakens with numbness, tingling and pain, and discomfort. Pain level varies throughout the day depending on activities.

### **Upper-Mid-Back:**

The pain is slight to moderate, and the symptoms occur intermittently in the upper and mid-back. The pain increases with twisting and turning at the waist, forward bending, pushing, pulling, and lifting and carrying. The patient complains of pulling, tightness, and crackling in the mid-back area. There are numbness and tingling, and muscle spasms.

### **Left Hip:**

The pain is moderate, and the symptoms occur intermittent in the left hip. There is radiating pain from the left hip into the leg accompanied by numbness. The pain increases with sitting and lying on her left side.

### **Bilateral Knees:**

The pain is slight to moderate, and the symptoms occur frequently in both knees, which is greater on the right side. The pain increases with flexing, extending, prolonged standing and walking, going up and down stairs, bending, stooping, squatting, and walking on uneven surfaces or slanted surfaces. There is popping in both knees, and the patient experiences locking and buckling episodes. The patient has lost balance as a result of the buckling. The patient has episodes of swelling in the knees. The patient is unable to kneel and squat. The patient has difficulty ascending and descending stairs and walks with an uneven gait.

### **Bilateral Feet:**

The pain is moderate, and the symptoms occur intermittently in the bilateral feet. There are episodes of swelling. There is numbness and tingling in both feet. The pain is aggravated by standing and walking over 20 minutes, flexing, extending, squatting, stooping, and standing.



Re: Patient – SEERAM, Sandra  
Report Date – August 08, 2022  
Page 8

The patient cannot hop, jump or run due to the pain. There is numbness and tingling in the toes. The patient limps while walking and ambulating.

**Psyche:**

The patient has episodes of anxiety, stress, and depression due to chronic pain and disability status. The patient denies suicidal ideation.

The patient has difficulty sleeping, often obtaining a few hours of sleep at a time. The patient feels fatigued throughout the day and finds herself lacking concentration and memory at times. The patient worries about her medical condition and the future.

**PAST MEDICAL HISTORY – “CONDITIONS, ILLNESSES AND/OR INJURIES PREDATING THE SUBSEQUENT INJURY AND LABOR DISABLING.”**

**Illnesses:**

She was diagnosed with fibromyalgia in 2017 at Kaiser by Dr. Chung.

She was diagnosed with degenerative disc disease and spondylosis in about 2018 and is medicated.

She was diagnosed with hypothyroidism in 2012 and is medicated.

She was diagnosed with nodules in her lungs and uses inhaler.

She is borderline diabetic.

She wears reading glasses.

She was diagnosed with skin condition in 2019 of discoloration of patches of skin on face and body called hyperkeratosis as she recalls and was informed it is associated with internal medical issues as she understands.

The patient was diagnosed in 2019 with Diverticulitis.

**Injuries:**

The patient denied any prior work-related injuries.

The patient denies any prior non-work-related injuries.

The patient denied any new injuries.

**Allergies:**

The patient is allergic to penicillin.

**Medications:**

Levothyroxine sodium since 2012 for a thyroid condition

Cymbalta since 2016 for anxiety and pain

Re: Patient – SEERAM, Sandra  
Report Date – August 08, 2022  
Page 9

Ibuprofen 600 mg for pain  
Citalopram hydrobromide she took medication for depression and anxiety from 2019-2020  
Mobic since 2009 for pain  
Flurbiprofen 20%  
Lidocaine HCL 5% topical cream  
Lansoprazole 15 for stomach upset  
Inhaler

**Surgeries:**

The patient denied any prior major surgeries.

**Hospitalization:**

The patient denied any hospitalizations.

**REVIEW OF SYSTEMS:**

**GENERAL:** Denies fever, weight loss, and malaise.  
The patient has had a history of night sweats since 2014 and has been on hormonal therapy since April of 2022.

**HEENT:** Denies sore throat, ear pain or nasal congestion.  

- She has blurry vision and headaches, which were labor disabling in the form of inability to see numbers, which transposing numbers affecting her job performance.

**CARDIAC:** Denies hypertension, chest pain, orthopnea, or palpitations.

**PULMONARY:** Denies shortness of breath, wheezing, hemoptysis, or productive cough.  
The patient has nodules on her lungs due to inhaling chemicals and dust while working for the subject employer. She reports shortness of breath when productive cough.

**GASTROINTESTINAL:** Denies hepatitis, ascites, abdominal pain, or jaundice.  
The patient has diverticulitis and abdominal pain.  
She was unable to eat at proper times, causing abdominal pain, which disrupted her work performance.

**NEUROLOGIC:** Denies migraine headaches, numbness, tingling, cramping, dementia, cerebral palsy, Alzheimer's disease, epilepsy, stroke, paralysis, or TIA.

She reports numbness in both legs and both hands, which was labor disabling in the form of trying to lift objects and getting from one place to another in a timely manner.

MUSCULOSKELETAL: See Current complaints/past Medical history.

HEMATOLOGIC: Denies easy bleeding or bruising.

ENDOCRINE: Denies polyuria or polydipsia.  
The patient reported hypothyroidism and was diagnosed in 2012. She recalls she had major menstrual bleeding and numbness and fatigue, which was labor disabling when not being able to rest and having to work extra hours.

GENITOURINARY: Denies hesitancy, urgency or frequency, nocturia, or bladder and/or bowel incontinence.

- The patient reports frequent urination since 2009. I was labor disabling due to excessive workload and unable to take bathroom breaks.

PSYCH: The patient reports a history of anxiety, stress, and depression due to cumulative trauma, chronic pain, and disability status. She relates her psychological condition was labor disabling, affecting her concentration and work performance.

OTHER: The patient reports circulatory system issues due to anxiety.

### **ACTIVITIES OF DAILY LIVING:**

#### **Reference for ADL values:**

Communication: As a result of the industrially-related injury, the patient states: No difficulty with writing, typing, and seeing 3/5.

Physical Activities: As a result of the industrially-related injury, the patient states: Difficulty with standing, sitting, reclining, walking, and going up and downstairs, with a rating of 3/5.

Sensory Function: As a result of the industrially-related injury, the patient states: Difficulty with tactile feeling with a rating of 3/5.

Hand Activities: As a result of the industrially-related injury, the patient states: Difficulty with grasping or gripping, lifting, and manipulating small items with a rating of 4/5.

Re: Patient – SEERAM, Sandra  
Report Date – August 08, 2022  
Page 11

Travel: As a result of the industrially-related injury, the patient states: Difficulty with riding in a car, driving a car, traveling by plane, and a restful night sleep pattern, with a rating of 4/5.

### **FAMILY HISTORY:**

Mother is 75 years old and has high blood pressure.

Her father passed away from pneumonia after a stroke and a fall. He had high blood pressure.

The patient has one brother and one sister. They are well and in good health.

There is no known history of colon cancer, prostate cancer, breast cancer, or heart problems.

### **SOCIAL HISTORY:**

The patient is married. She has two children.

The patient has completed two years of college, and she has her associate degree.

The patient consumes wine occasionally and does not smoke.

The patient does not exercise.

The patient participates and does not participate in any sports activities.

### **Physical Evaluation (August 08, 2022) – Positive Findings:**

#### **General Appearance:**

The patient is a 53-year-old female, right-hand dominant who appeared reported age, and was well-developed, well-nourished, and well-proportioned. She was alert, cooperative and somewhat confused.

#### **Vital Signs:**

|                 |          |
|-----------------|----------|
| Pulse:          | 85       |
| Blood Pressure: | 92/66    |
| Height:         | 5'4-1/2" |
| Weight:         | 146      |

Cervical Spine:

**Tenderness to palpation was noted over the bilateral paravertebral and upper trapezius musculature with tenderness and hypomobility present at C4 to C7 vertebral regions with greatest tenderness over the bilateral facet joints.**

**Bilateral shoulder depression tests were positive.**

**Cervical spine ranges of motion were decreased and painful. Please see attached formal ranges of motion study performed utilizing dual electronic inclinometers.**

Shoulders & Upper Arms:

Deformity, dislocation, edema, swelling, erythema, surgical scars and lacerations are not present upon visual examination of the shoulders. The shoulders are held in a nonantalgic position.

Tenderness and spasm are not present over the supraspinatus musculature, infraspinatus musculature, teres (minor/major) musculature, subscapularis musculature, periscapular musculature and deltoid musculature bilaterally. There is no tenderness over the subacromial bursa and subdeltoid bursa bilaterally. The acromioclavicular joint, glenohumeral joint and clavicle are not tender bilaterally. The triceps and biceps brachii muscles are without tenderness and spasm bilaterally and appear intact and without evidence of rupture.

Apprehension, Dugas, Hawkins and Impingement Sign orthopedic tests are negative bilaterally.

Ranges of motion of the right shoulder and left shoulder were performed without pain, spasm or weakness.

| <i>Shoulder Ranges Of Motion Testing</i> |        |             |              |
|--|--------|-------------|--------------|
| Movement                                 | Normal | Left Actual | Right Actual |
| Flexion                                  | 180    | 180         | 180          |
| Extension                                | 50     | 50          | 50           |
| Abduction                                | 180    | 180         | 180          |
| Adduction                                | 50     | 50          | 50           |
| Internal Rotation                        | 90     | 90          | 90           |
| External Rotation                        | 90     | 90          | 90           |

Elbows & Forearms:

Deformity, dislocation, edema, swelling, erythema, scars and lacerations are not present upon visual examination of the elbow bilaterally.

Tenderness is not present over the lateral epicondyle, medial epicondyle and cubital tunnel bilaterally. Tenderness is not present over the flexor muscle group and extensor muscle group of the forearm bilaterally.

Valgus and Varus Stress Tests are negative. Cozens' (resisted wrist extension) and Golfers' (resisted wrist flexion) tests are negative bilaterally.

Tinel's sign at the right elbow and left elbow is negative.

Ranges of motion for the right and left elbows were accomplished without pain and spasm and were as follows:

| <i>Elbow Range of Motion Testing</i> |        |             |              |
|--------------------------------------|--------|-------------|--------------|
| Movement                             | Normal | Left Actual | Right Actual |
| Flexion                              | 140    | 140         | 140          |
| Extension                            | 0      | 0           | 0            |
| Supination                           | 80     | 80          | 80           |
| Pronation                            | 80     | 80          | 80           |

Wrists & Hands:

**Tenderness was noted over the volar crease over the carpal tunnel and carpals.**

**Tinel's sign were positive bilaterally. Median nerve compression test was positive bilaterally with reproduction of numbness and tingling of bilateral hands.**

**Ranges of motion of the bilateral wrists were normal with pain at extremes.**

| <i>Wrist Range of Motion Testing</i> |        |             |              |
|--------------------------------------|--------|-------------|--------------|
| Movement                             | Normal | Left Actual | Right Actual |
| Flexion                              | 60     | 60          | 60           |
| Extension                            | 60     | 60          | 60           |
| Ulnar Deviation                      | 30     | 30          | 30           |
| Radial Deviation                     | 20     | 20          | 20           |

Finger ranges of motion were performed without pain. Triggering of the digits and mechanical block is not present. Tenderness is not present at the digits. Thumb abduction is 90 degrees bilaterally. Thumb adduction reaches the head of the 5th metacarpal bilaterally.

Bilateral hand digit range of motion grossly within normal range.

Grip Strength Testing:

Grip strength testing was performed utilizing the Jamar Dynamometer at the third notch, measured in kilograms, on 3 attempts and produced the following results:

**Left: 0/2/2**  
**Right: 5/0/0**

Motor Testing of the Cervical Spine and Upper Extremities:

Deltoid (C5), Biceps (C5), Triceps (C7), Wrist Extensor (C6), Wrist Flexor (C7), Finger Flexor (C8) and Finger Abduction (T1) motor testing is normal and 5/5 bilaterally **with the exception of finger flexion 4/5 bilaterally, all other myotomes 5/5.**

Deep Tendon Reflex Testing of the Cervical Spine and Upper Extremities:

Biceps (C5, C6), Brachioradial (C5, C6) and Triceps (C6, C7) deep tendon reflexes are normal and 2/2 bilaterally.

Sensory Testing:

C5 (deltoid), C6 (lateral forearm, thumb & index finger), C7 (middle finger), C8 (little finger & medial forearm), and T1 (medial arm) dermatomes are intact bilaterally as tested with a Whartenberg's pinwheel **with the exception of generalized hypoesthesia noted in the entire right upper extremity from the shoulder extending to the hand.**

| <i>Upper Extremity Measurements in Centimeters</i> |             |             |
|--|-------------|-------------|
| Measurements                                       | Left        | Right       |
| Biceps   | <b>28</b>   | <b>28</b>   |
| Forearms   | <b>19.5</b> | <b>19.5</b> |

Thoracic Spine:

Gross edema, swelling, erythema and scars are not present upon visual examination of the thoracic spine. The thoracic spine has a normal kyphotic curvature.

Tenderness and spasm is not present over the paravertebral musculature, trapezius, rhomboid, latissimus dorsi musculature and interscapular region bilaterally. Tenderness and hypomobility is not present over the vertebral regions from T1 to T12.

Kemp's test is negative.

Thoracic spine ranges of motion were performed without pain and spasm.

| <i>Thoracic Spine Range of Motion Testing</i> |        |        |
|---|--------|--------|
| Movement                                      | Normal | Actual |
| Flexion                                       | 60     | 60     |
| Extension                                     | 0      | 0      |
| Right Rotation                                | 30     | 30     |
| Left Rotation                                 | 30     | 30     |

Lumbar Spine:

Gross edema, swelling, erythema and scars are not present upon visual examination of the lumbar spine. The lumbar spine has a normal lordotic curvature.

Tenderness and spasm is not present over the paravertebral musculature, sacroiliac joints and sciatic notches bilaterally. Tenderness and spasm is not present over the sacrum and coccyx bilaterally. Tenderness and hypomobility is not present over the vertebral regions from L1 to L5.

Minor's sign and Milgram's test are negative. Braggard's test and Sacroiliac compression tests are negative bilaterally.

Lumbar spine ranges of motion were performed without pain and spasm.

| <i>Lumbar Spine Range of Motion Testing</i> |        |        |
|---|--------|--------|
| Movement                                    | Normal | Actual |
| Flexion                                     | 60     | 60     |
| Extension                                   | 25     | 25     |
| Right Lateral Bending                       | 25     | 25     |
| Left Lateral Bending                        | 25     | 25     |

Hips & Thighs:

Right Hip:

Deformity, dislocation, edema, swelling, erythema, scars and lacerations are not present upon visual examination of the right hip and thigh.

Tenderness and spasm is not present over the greater trochanteric region, hip bursa, hip abductor, hip adductor, quadriceps, biceps femoris musculature and femoroacetabular joint.

Patrick Fabere test and Hibb's test are negative on the right.



Left Hip:

**Examination revealed tenderness over the hip bursa and greater trochanter as well as femoroacetabular joint with greatest tenderness over the anterior aspect.**

**Left Patrick Fabere test is positive for increased hip pain.**

Right hip ranges of motion were within normal limits. **Left hip ranges of motion were decreased and painful, measured as follows:**

| <i>Hip Range of Motion Testing</i> |        |             |              |
|------------------------------------|--------|-------------|--------------|
| Movement                           | Normal | Left Actual | Right Actual |
| Flexion                            | 120    | <b>90</b>   | 120          |
| Extension                          | 30     | <b>25</b>   | 30           |
| Abduction                          | 45     | <b>30</b>   | 45           |
| Adduction                          | 30     | <b>15</b>   | 30           |
| External rotation                  | 45     | <b>25</b>   | 45           |
| Internal rotation                  | 45     | <b>30</b>   | 45           |

Knees & Lower Legs:

Visual examination of knees and lower legs does not identify deformity, dislocation, edema, swelling, erythema, scars and lacerations.

Tenderness is not present over the quadriceps tendon, patella, infrapatellar tendon, tibial tuberosity, medial joint line, lateral joint line and popliteal fossa bilaterally. Palpation of the lower leg muscles/regions was unremarkable for tenderness at the gastrocnemius, tibialis anterior (*dorsiflexion & inversion*) and peroneal musculature (*lateral ankle-eversion*) bilaterally.

McMurray's test, Varus Stress test, anterior drawer test and posterior drawer test are negative.

Range of motion of the knees was without pain, spasm, weakness, crepitus or instability bilaterally.

The patient was able to squat without knee pain or weakness.

| <i>Knee Range of Motion Testing</i> |        |             |              |
|-------------------------------------|--------|-------------|--------------|
| Movement                            | Normal | Left Actual | Right Actual |
| Flexion                             | 135    | 135         | 135          |
| Extension                           | 0      | 0           | 0            |

Ankles & Feet:

Examination of ankles and feet did not demonstrate gross deformity, dislocation, amputation, edema, swelling, erythema, scars, lacerations, hallux valgus and hammertoes. The foot arch height is normal and without pes planus and pes cavus.

Tenderness is not present of digits 1 through 5, including metatarsals, cuneiforms, navicular, cuboid, talus and calcaneus. Tenderness is not present at the distal tibia, distal fibula, talonavicular joint, anterior talofibular ligament and deltoid ligament. There is no medial ankle instability or lateral ankle instability bilaterally. The Achilles tendon is intact. Tenderness is not present over the tarsal tunnel, sinus tarsi and tibialis posterior tendons (*medial ankle-plantarflexion & inversion*) bilaterally.

Anterior drawer test, posterior drawer test and Tinel's sign are negative bilaterally. The dorsalis pedis pulses are present and equal bilaterally.

Ankle ranges of motion were performed without pain, spasm, weakness, crepitus or instability bilaterally.

| <i>Ankle Range of Motion Testing</i>      |        |             |              |
|---|--------|-------------|--------------|
| Movement                                  | Normal | Left Actual | Right Actual |
| Metatarsophalangeal joint (MPJ) Extension | 60     | 60          | 60           |
| MPJ Flexion                               | 20     | 20          | 20           |
| Ankle Dorsiflexion                        | 20     | 20          | 20           |
| Ankle Plantar Flexion                     | 50     | 50          | 50           |
| Inversion (Subtalar joint)                | 35     | 35          | 35           |
| Eversion (Subtalar joint)                 | 15     | 15          | 15           |

Motor, Gait & Coordination Testing of The Lumbar Spine and Lower Extremities:

Ankle Dorsiflexion (*L4*), Great Toe Extension (*L5*), Ankle Plantar Flexion (*L5/S1*), Knee Extension (*L3, L4*), Knee Flexion, Hip Abductor and Hip Adductor motor testing was normal and 5/5 **with the exception of left hip flexion and abduction 4/5, all other myotomes 5/5.**

**Squatting was positive for left hip pain.**

Heel and toe walking was performed well.

The patient's gait was within normal limits.

Deep Tendon Reflex Testing of The Lumbar Spine and Lower Extremities:

Ankle (*Achilles-S1*) and Knee (*Patellar Reflex-L4*) deep tendon reflexes are normal and 2/2.

Re: Patient – SEERAM, Sandra  
Report Date – August 08, 2022  
Page 18

Sensory Testing:

L3 (*anterior thigh*), L4 (*medial leg, inner foot*), L5 (*lateral leg and midfoot*) and S1 (*posterior leg and outer foot*) dermatomes are intact bilaterally upon testing with a pinwheel **with the exception of hypoesthesia in the left L4, L5 and S1 dermatomal innervation.**

Girth & Leg Length (Anterior Superior Iliac Spine to Medial Malleoli) measurements were taken of the lower extremities, as follows in centimeters:

| <i>Lower Extremity Measurements Circumferentially &amp; Leg Length in Centimeters</i> |             |             |
|---|-------------|-------------|
| Measurements (in cm)  | Left        | Right       |
| Thigh - 10 cm above patella with knee extended  | <b>47.5</b> | <b>47</b>   |
| Calf - at the thickest point  | <b>30</b>   | <b>29.5</b> |
| Leg Length - Anterior Superior Iliac Spine To Medial Malleolus                        | <b>103</b>  | <b>103</b>  |

**REVIEW OF RECORDS:**

**See Addendum #1**

**Diagnostic Impressions:**

1. Cervical spine myofasciitis, M79.1.
2. Cervical facet-induced versus discogenic pain, M53.82.
3. Cervical radiculitis versus brachial plexopathy, M54.12, G54.0.
4. Bilateral carpal tunnel syndrome, G56.03.
5. Left hip trochanteric bursitis, M70.62.
6. DJD of left hip, rule out, and aggravation, M16.12.
7. Bilateral knee arthralgia – normal physical examination, M25.569.
8. Bilateral foot arthralgia versus plantar fasciitis – normal physical exam, M25.579/ M72.2.
9. Fibromyalgia, M79.7.
10. Hypothyroidism, E03.9.
11. Lung nodules with respiratory issues requiring use of inhaler, R91.1.
12. Borderline diabetes as patient reports, R73.03.

Re: Patient – SEERAM, Sandra  
Report Date – August 08, 2022  
Page 19

13. Deteriorating vision, H54.7.
14. Hyperkeratosis, L85.9.
15. Diverticulitis, K57.92.
16. Anxiety and depression, F41.9, F34.1.

### **SUMMARY, CONCLUSIONS & RECOMMENDATIONS:**

Please note, the patient reports she did have MRI of the cervical spine in April of 2022 and I am requesting that study to be forwarded to my attention for review to avoid duplication of services; however, I do see an earlier MRI study referenced in the record review. I am also requesting x-rays of the wrists, which the patient underwent as well, as well as left hip x-rays and MRI. Also, I am requesting that the NCV/EMG study the patient underwent of her upper extremities, which showed carpal tunnel bilaterally, to be forwarded to my attention for review as soon as possible to avoid duplication of services; however, I see it reviewed in the Orthopedic PME Reports indicating bilateral carpal tunnel syndrome.

Please note, this patient has multiple medical conditions and for determination of all her issues related to the subsequent injury and benefit trust fund, this patient will need to see multiple medical specialist as indicated below. Please note this patient's Cervical MRI study showed spinal canal stenosis and this may be the cause of the leg weakness as reported to Kaiser as in the medical records from Kaiser.

The patient worked for the referenced employer for over 30 years. She didn't have concurrent employment. By reviewing her medical records, this patient did not have any pre-existing orthopedic conditions. The records from Kaiser show the patient developed neck, upper extremity and lower extremity issues while working for JP Morgan Chase. This patient also developed multiple medical conditions during the time of her employment that include upper and lower respiratory issues, upper and lower gastrointestinal issues, endocrine disorders, psych conditions, etc. as per the review of records section.

### **Medical Causation Regarding AOE/COE:**

In my opinion, it is within a reasonable degree of medical probability that the causation of this patient's injuries, resultant conditions, as well as need for treatment with regards to the cervical spine and wrists/hands is secondary to the Subsequent Injury CT: 05/17/2018 - 05/18/2019 while working for JP Morgan Chase for over 30 years. As related to left hip, I defer causation to a rheumatologist. Please note that Orthopedic PQME Dr. Joanne Halbrecht did find left hip tenderness, but she also found every other body part to be tender and this was non conclusive. As related headaches and lower extremity hypoesthesia, I defer causation to a neurologist as this patient's lumbar spine exam was within normal limits. Please note this patient

Re: Patient – SEERAM, Sandra  
Report Date – August 08, 2022  
Page 20

has found to have upper and lower respiratory issues that are non industrial as per PQME Dr. Steward Lonky, but impairment was not calculated.

Medical literature has established that, awkward postures, repetition, repetitive motion, excessive force, vibrations, poor designed tools, and even static posture can cause sprains, strains as well as and musculoskeletal disorders and other degenerative changes.

1. Centers for Disease Control and Prevention. [“Work-Related Musculoskeletal Disorders and Ergonomics.”](#) February, 2018. Accessed April 30, 2018.
2. <https://www.ncbi.nlm.nih.gov/pmc/articles/PMC2016244/pdf/11228032.pdf>
3. <https://www.ncbi.nlm.nih.gov/pmc/articles/PMC1743087/pdf/v080p00438.pdf>
4. <https://www.ninds.nih.gov/health-information/disorders/repetitive-motion-disorders>
5. <https://www.jabfm.org/content/16/6/533.full>
6. [https://www.osha.gov/sites/default/files/2018-12/fy11\\_sh-22310-11\\_PreventingSprainsStrains\\_RSI.pptx](https://www.osha.gov/sites/default/files/2018-12/fy11_sh-22310-11_PreventingSprainsStrains_RSI.pptx)
7. <https://my.clevelandclinic.org/health/diseases/17424-repetitive-strain-injury>
8. <https://www.betterhealth.vic.gov.au/health/healthy-living/workplace-safety-overuse-injuries>
9. OrthoInfo. [“Carpal Tunnel Syndrome.”](#) July, 2016. Accessed April 30, 2018.
10. Stokes IA, Iatridis JC. Mechanical conditions that accelerate intervertebral disc degeneration: overload versus immobilization. *Spine (Phila Pa 1976)*. 2004 Dec 1;29(23):2724-32. doi: 10.1097/01.brs.0000146049.52152.da. PMID: 15564921; PMCID: PMC7173624.
11. Bass, E. (2012, March 31). Tendinopathy: Why the difference between tendinitis and tendinosis matters. *International Journal of Therapeutic Massage & Bodywork*  
<http://www.ncbi.nlm.nih.gov/pmc/articles/PMC3312643/>
12. American Society for Surgery of the Hand. [“Carpal Tunnel Syndrome.”](#) 2015. Accessed April 30, 2018.
13. Cubital tunnel syndrome. (n.d.)  
<http://www.assh.org/handcare/hand-arm-conditions/cubital-tunnel>
14. Helliwell, P.S., ... (2004, March). Repetitive strain injury. *Postgraduate Medical Journal*  
<http://pmj.bmj.com/content/80/946/438.full>
15. Prevent RSI. (2016, July 22)  
<http://www.nhs.uk/Livewell/workplacehealth/Pages/rsi.aspx>
16. Ramazzini, B. (2001, September). De morbis artificum diatriba [diseases of workers]. *American Journal of Public Health*  
<http://www.ncbi.nlm.nih.gov/pmc/articles/PMC1446785/>
17. Repetitive strain injury. (2015, November 18)  
<http://www.hse.ie/eng/health/az/R/Repetitive-strain-injury/Diagnosing-repetitive-strain-injury.html>
18. Trigger finger. (n.d.)  
<http://www.assh.org/handcare/hand-arm-conditions/trigger-finger>
19. Types of repetitive strain injury. (2010)  
<http://www.hse.ie/eng/health/az/R/Repetitive-strain-injury/Diagnosing-repetitive-strain-injury.html>

In my opinion, it is medically reasonable that the job duties the patient performed as per the job description section, particularly but not exclusively: the repetitive typing, prolonged posturing with the neck, lifting, bending, etc. were sufficiently strenuous that over time her performance of these activities led to neuromusculoskeletal overload causing her diagnoses and contributed to the above mentioned injuries.

**Specialty Medical Evaluations recommended** to further evaluate nature and extent of injury:

- **Internist** – Further evaluation of fibromyalgia, respiratory issues, gastrointestinal issues, diabetes, hypothyroidism.
- **Neurologist** – For further evaluation of headaches and neurological issues.
- **Pulmonologist** - for further evaluation of pulmonary/respiratory issues.
- **Rheumatologist**– for further evaluation of left hip and specifically fibromyalgia.
- **Endocrinologist** – for further evaluation of diabetes, hypothyroidism and to rule out other endocrinological disorders.
- **Dermatology** – for further evaluation of hyperkeratosis.
- **Gastroenterology** – for further evaluation of gastrointestinal issues and diverticulitis.
- **Ophthalmology versus Optometry** – for further evaluation of loss of vision.

Please note that I did indicate medical specialists beyond internist for specific issues/conditions that overlap with the internist, but would provide a more in-depth and specific evaluation as related to the conditions/body systems referenced above. The specialists this patient has seen up until now, did not rate or adequately evaluate / consider pre-existing conditions and this patient requires SIBTF evaluations as mentioned. Once the SIBTF specialty evaluations are complete, I would need to review the records to determine if there are any changes in my opinions.

**AMA Impairment, 5<sup>th</sup> Edition Analysis, Causation, Pre and Post Subsequent Injury Apportionment, Maximum Medical Improvement, Work Restrictions and Discussions:**

- A. **Causation (Subsequent Injury):** As per currently available medical records and history as per the patient, it is within reasonable medical probability that causation of **neck and bilateral wrists/hands** is secondary to the subsequent injury Subsequent Injury CT: 05/17/2018 - 05/18/2019 while working for JP Morgan Chase as discussed within this report and summarized in the “discussion section.” I reserve the right to change my opinions should additional medical records come forward.

**Permanent & Stationary Status:**

- B) **Following the subsequent Work Injury:** It is within a reasonable medical probability this patient has reached maximum medical improvement **as related to neck, bilateral wrists/hands and left hip** and is permanent and stationary following the Subsequent Injury CT: 05/17/2018 - 05/18/2019 while working for JP Morgan Chase. It is within reasonable medical probability that the patient’s subsequent injury is compensable and labor disabling with a permanent partial disability.

## **AMA IMPAIRMENT & APPORTIONMENT ANALYSIS**

1. Spine: Cervical
2. Upper Extremities: Bilateral Wrists
3. Lower Extremities: Left Hip

Spine:

### **A. Cervical Spine:**

1. Cervical Spine: Patient qualifies for **DRE** category II, 8% whole person impairment by referencing Table 15-5 on page 392 due to asymmetric loss range of motion and in view of her pain levels.

**Pre-existing Cervical impairment** - I apportion **0%** for **cervical spine**. Please note I did not see any medical issues documented that predate this patient's employment with JP Morgan for over 30 years.

**Subsequent Injury Cervical** – I apportion 100% to subsequent injury **which equates to 8% whole person impairment**.

- A. Left Wrist/Hand:** Minor grip strength impairment is 30% upper extremity impairment by referring tables 16-32 and 16-34 on page 509 due to 94% SLI; Upper extremity impairment converts to 18% whole person impairment.  
**Pre-existing** - I apportion 0% for left wrist/hand. Please note I did not see any medical issues documented that predate this patient's employment with JP Morgan for over 30 years. Orthopedic PQME Dr. Halbrecht indicated some non-industrial apportionment for carpal tunnel due to non industrial Vitamin D deficiency, however, it is important to keep in mind this deficiency occurs with decreased exposure to sunlight and this patient worked indoors for years fulltime. Furthermore the Internist PQME was silent on this issue.  
**Subsequent Injury** – I apportion 100% **which equates to 18% whole person impairment**.
- B. Right Wrist/Hand:** Major grip strength impairment is 30% upper extremity impairment by referring tables 16-32 and 16-34 on page 509 due to 91% SLI, which equates to 18% whole person impairment.  
**Pre-existing** - I apportion 0% for right wrist/hand. Please note I did not see any medical issues documented that predate this patient's employment with JP Morgan for over 30 years. Orthopedic PQME Dr. Halbrecht indicated some non-industrial apportionment for carpal tunnel due to non industrial Vitamin D deficiency, however, it is important to keep in mind this deficiency occurs with decreased exposure to sunlight and this patient worked indoors for years fulltime. Furthermore the Internist PQME was silent on this issue.

**Subsequent Injury** – I apportion 100% which equates to 18% whole person impairment.

LOWER EXTREMITY:

- A. **Left Hip range of motion**, 15% lower extremity impairment by referencing table 17-9 on page 537, it converts to 6% whole person impairment by referencing table 17-3 on page 527.

**Pre-existing** - I apportion 0% for left hip as I do not recall seeing any medical records that predate the subsequent injury nor any other injuries specific injuries that contributed to the left hip.

**Subsequent Injury** – I am unable to determine apportionment at this time to the subsequent Injury as I don't know what caused the onset of the left hip issue.

**Total whole persona impairment as related to above: 50%** by adding bilateral wrists with cervical spine with left hip whole person impairment. **Please note that due to synergistic effect, impairments were added versus combined per the Kite Case.**

**Final Apportionment Analysis:**

- A. **Total Whole Person Impairment Apportioned to Subsequent Injury = 93%** by adding above referenced Calculated Subsequent Injury Whole Person Impairments as per undersigned with 10% Upper GI with 3% lower GI (2.5% rounded up) as per Internist Dr. Lonky with 30% Psych per Dr. Curtis.

**Please note that due to synergistic effect, impairments were added versus combined per the Kite Case.**

- B. **Total Whole Person Impairment that I am unable to establish apportionment = 3% upper extremity impairment** (2.5% rounded up) as Dr. Lonky stated Lower GI impairment is 5% and apportioned 50% to non industrial cases, but didn't further elaborate. Furthermore there are upper and lower respiratory issues as PQME Dr. Lonky indicated, but he didn't calculate impairment and simply stated it was non industrial due to deviated septum.

**Permanent Work Restrictions Currently:**

Cervical Spine: No very heavy lifting. No prolonged posturing with head/neck.

Bilateral Wrists: No repetitive or prolonged activities with fingers/hands that include typing and using computer mouse. No heavy lifting. Patient to use carpal tunnel splints at night and during activities as needed.



Re: Patient – SEERAM, Sandra  
Report Date – August 08, 2022  
Page 24

Left hip: No heavy or repetitive squatting, no repetitive kneeling/stooping nor climbing.

**Subjective Factors of Disability:**

Please see current complaints section of this report.

**Objective Factors of Disability:**

Please see positive findings on physical exam, diagnostic studies reviewed under “review of diagnostic studies” section of this report.

**Vocational Rehabilitation Benefits:**

In my opinion the patient is a qualified injured worker, however this patient was seen by a vocational rehabilitation specialist Madonna Garcia and I need to review her report to determine if that patient is not amenable to any form of rehabilitation or if a she sustained a total loss in their capacity to meet any occupational demands.

**CONCLUSIONS:**

I have reviewed Labor Code 4751 and there appears to be adequate evidence to conclude, with reasonable medical probability, that Ms. Seeram meets initial SIBTF criteria.

1. There does appear to be adequate evidence to conclude with reasonable medical certainty that Ms. Seeram had previous partial disability as per the work restrictions outlined by the undersigned.
2. The combined effect of the preexisting impairment and the impairment due to the subsequent injury is likely to result in a permanent disability equal to, or greater than, 70%.
3. The permanent disability resulting from the subsequent injury, when considered alone and without regard to or adjustment for the occupation or age of the employee, exceeds the 35% threshold for Labor Code 4751.

**REASONS FOR OPINIONS:**

1. The consistency of the mechanism of injury with the patient’s complaints and the consistency of the patient’s description of injuries in relation to the submitted medical records.
2. Review of available medical records.

Re: Patient – SEERAM, Sandra  
Report Date – August 08, 2022  
Page 25

3. Perceived credibility of Ms. Seeram and her internally consistent statements and physical action.
4. My experience in treating similar patients and injuries over the past 20 years.

### **LC 4751 Compensation for specified additions to permanent partial disabilities**

If an employee who is permanently partially disabled receives a subsequent compensable injury resulting in additional permanent partial disability so that the degree of disability caused by the combination of both disabilities is greater than that which would have resulted from the subsequent injury alone, and the combined effect of the last injury and the previous disability or impairment is a permanent disability equal to 70 percent or more of total, he shall be paid in addition to the compensation due under this code for the permanent partial disability caused by the last injury compensation for the remainder of the combined permanent disability existing after the last injury as provided in this article; provided that either (a) the previous disability or impairment affected a hand, an arm, a foot, a leg, or an eye, and the permanent disability resulting from the subsequent injury affects the opposite and corresponding member, and such latter permanent disability, when considered alone and without regard to, or adjustment for, the occupation or age of the employee is equal to 5 percent or more of total, or (b) the permanent disability resulting from the subsequent injury, when considered alone and without regard to or adjustment for the occupation or the age of the employee, is equal to 35 percent or more of total.

### **DISCLOSURE STATEMENT**

I derived the above opinions from the oral history as related by the patient, revealed by the available medical records, diagnostic testing, credibility of the patient, examination findings and my clinical experience. This evaluation was carried out at 6221 Wilshire Boulevard, Suite 604, Los Angeles, California 90048. I prepared this report, including any and all impressions and conclusions described in the discussion.

In compliance with recent Workers' Compensation legislation (Labor Code Section 4628 (b)): I declare that the history was taken by Irma Chavira and I personally reviewed the history with the patient (essentially the history was taken twice), I performed the physical examination, reviewed the document and reached a conclusion. The names and qualifications of each person who performed any services in connection with the report are Acu Trans Solution, LLC, who transcribed this report and I proofread and edited the final draft prior to signing the report in compliance with the guidelines established by the Industrial Medical Council or the Administrative Director pursuant to paragraph (5) of subdivision (j) of Section 139.2.

In compliance with recent Workers' Compensation legislation (Labor Code Section 4628 (j)): "I declare under penalty of perjury that the information contained in this report and its attachments, if any, is true and correct to the best of my knowledge and belief, except as to information I have indicated I received from others. As to that information, I declare under penalty of perjury that the information accurately describes the information provided to me and, except as noted herein, that I believe it to be true."

In compliance with recent Workers' Compensation legislation (Labor Code Section 5703 under AB 1300): "I have not violated Labor Code Section 139.3 and the contents of this report are true and correct to the best of my knowledge. This statement is made under penalty of perjury and is consistent with WCAB Rule 10978."

Re: Patient – SEERAM, Sandra  
Report Date – August 08, 2022  
Page 26

The undersigned further declares that the charges for this patient are in excess of the RVS and the OMFS codes due to high office and staff costs incurred to treat this patient, that the charges are the same for all patients of this office, and that they are reasonable and necessary in the circumstances. Additionally, a medical practice providing treatment to injured workers experiences extraordinary expenses in the form of mandated paperwork and collection expenses, including the necessity of appearances before the Workers' Compensation Appeals Board. This office does not accept the Official Medical Fee Schedule as prima facie evidence to support the reasonableness of charges. I am a board-certified Doctor of Chiropractic, a state-appointed Qualified Medical Evaluator, a Certified Industrial Injury Evaluator and certified in manipulation under anesthesia. Based on the level of services provided and overhead expenses for services contained within my geographical area, I bill in accordance with the provisions set forth in Labor Code Section 5307.1.

NOTE: The carrier/employer is requested to immediately comply with 8 CCR Section 9784 by overnight delivery service to minimize duplication of testing/treatment. This office considers "all medical information relating to the claim" to include all information that either has, will, or could reasonably be provided to a medical practitioner for elicitation of medical or medical-legal opinion as to the extent and compensability of injury, including any issues regarding AOE/COE - to include, but not be limited to, all treating, evaluation, and testing reports, notes, documents, all sub rosa films, tapes, videos, reports; employer-level investigation documentation including statements of individuals; prior injury documentation; etc. This is a continuing and ongoing request to immediately comply with 8 CCR Section 9784 by overnight delivery service should such information become available at any time in the future. Obviously, time is of the essence in providing evaluation and treatment. Delay in providing information can only result in an unnecessary increase of treatment and testing costs to the employer. I will assume the accuracy of any self-report of the examinee's employment activities, until and unless a formal Job Analysis or Description is provided. Should there be any concern as to the accuracy of the said employment information, please provide a Job Analysis/Description as soon as possible.

I request to be added to the Address List for Service of all Notices of Conferences, Mandatory Settlement Conferences and Hearings before the Workers' Compensation Appeals Board. I am advising the Workers' Compensation Appeals Board that I may not appear at hearings or Mandatory settlement Conferences for the case in chief. Therefore, in accordance with Procedures set forth in Policy and Procedural Manual Index No. 6.610, effective February 1, 1995, I request that defendants, with full authority to resolve my lien, telephone my office and ask to speak with me.

The above report is for medicolegal assessment and is not to be construed as a report on a complete physical examination for general health purposes. Only those symptoms which I believe have been involved in the injury, or might relate to the injury, have been assessed. Regarding the general health of the patient, the patient has been advised to continue under the care of and/or to get a physical examination for general purposes with a personal physician.

I declare under penalty of perjury under the laws of the State of California that the above is true and correct.

Re: Patient – SEERAM, Sandra  
Report Date – August 08, 2022  
Page 27

Sincerely,

A handwritten signature in black ink, appearing to read "Eric E. Gofnung". The signature is fluid and cursive, with the first name "Eric" being the most prominent.

---

Eric E. Gofnung, D.C.  
*Manipulation Under Anesthesia Certified*  
*State Appointed Qualified Medical Evaluator*  
*Certified Industrial Injury Evaluator*

Signed this 4<sup>th</sup> day of September 2022, in Los Angeles, California.

## **ADDENDUM 1 - REVIEW OF RECORDS**

Pursuant to Cal Code Regs., Title 8, § 9793(n) the parties attested to 6263 pages being provided for my review which have been received and reviewed by myself in preparation of this report.

### **A - Review of Legal Records**

- 1) June 20, 2022, Attestation from Applicant Attorney Natalia Foley, Esq. attesting to 6263 pages being sent to Dr. Gofnung for his upcoming appointment on August, 08, 2022.
- 2) Demographics: DOI: CT: 05/17/2018 - 05/18/2019. Occupation: Branch manager. Industrial Body Parts Claimed: Eye, neck, upper extremities, back, shoulder(s), lower extremities, digestive system, respiratory system, skin (dermatitis, etc.), digestive system, nervous system. Non-industrial Preexisting: Depression, arthritis blurry vision gastro back up & low extremities.
- 3) June 02, 2022, Cover Letter for SIBTF Medical Evaluation, Natalia Foley, Esq (Workers Defenders Law Group): DOI: CT: 05/17/2018 - 05/18/2019. This office represents the above referenced applicant. You (Dr. Gofnung) have been selected to act in the capacity of Medical Evaluator in regard to the applicant's Subsequent Injury Benefit Trust Fund Claim in your medical specialty. You are specifically asked to provide a medical legal evaluation in your area of expertise.

Please provide a medical legal evaluation and address the issue of causation of any injury within your area specialty.

Please provide your opinion if any other referral is necessary.

It is requested that a determination be made regarding any medical issues and disability within your area of specialty. Please provide a permanent impairment rating per the AMA guides 5<sup>th</sup> edition and address the issue of apportionment per LC section 4751 in regard to a particular period of time as follow:

- 1) Pre-existing condition**
- 2) Subsequent injury**
- 3) Current condition (post-industrial)**

Please cover in your report the following topics:

- Subjective complaints
- Objective factors or findings
- Current diagnosis and impairment rating
- Occupational history

- Past medical history
- Prior injuries
- Pre-existing **labor disabling** condition
- Rating of pre-existing labor disabling conditions
- History of subsequent injuries
- Impairment rating of subsequent injuries
- Subsequent injuries causation
- Apportionment of current condition to pre-existing and subsequent injuries
- Disability status & permanent work restrictions if any
- Activities of daily living

**Please answer the following questions within the scope of your specialty:**

- 1) On the day of your evaluation does the worker have a permanent impairment of any body parts **within your specialty?**
- 2) **IF YES**, is the worker 'condition permanent and stationary as of today?
- 3) **IF YES**, what is this impairment rating as of today, the date of your evaluation?
- 4) What kind of current work restrictions worker has due to his permanent impairment?
- 5) Did worker have a preexisting condition within the scope of your specialty?
- 6) **IF YES**, please answer the following questions:
  - (a) Was that preexisting condition partially labor disabling and could have been rated as permanent partial disability ("PPD") at the time worker suffered the subsequent industrial injury?
  - (b) Was that preexisting condition aggravated during the time of the subsequent employment?
  - (c) Did worker have a subsequent injury **within the scope of your specialty?**
  - (d) Did the subsequent industrial injury result in additional PPD?
- 7) Please APPORTION worker's condition as of today to the following:
  - (a) pre-existing condition
  - (b) subsequent injury
  - (c) post-subsequent injury

- 8) Is the combination of the preexisting disability and the disability from the subsequent industrial injury greater than that which would have resulted from the subsequent industrial injury alone?
- 9) Did the subsequent industrial injury rate to a 35% disability without modification for age and occupation:
  - (a) within the scope of your specialty?
  - (b) within the multidisciplinary combined rating (if known)?
- 10) Did the pre-existing disability affect an upper or lower extremity or eye?
- 11) Did the subsequent industrial permanent disability affect the opposite or corresponding body part?
- 12) Is the total disability equal to or greater than 70% after modification?
  - (a) within the scope of your specialty?
  - (b) within the multidisciplinary combined rating (if known)?
- 13) Is the employee 100% disabled or unemployable from other pre-existing disability and subsequent injuries together?
  - (a) within the scope of your specialty?
  - (b) within the multidisciplinary combined rating (if known)?

**Rating Determination:** When you rate pre-existing condition, please remember, that the prior labor disabling disability is not rated separately in the SIBTF case. SIBTF liability is not determined by rating the prior disability alone. The percentage of permanent disability from the prior disability is not a relevant factor in determining SIBTF eligibility [Subsequent Injuries Fund v. Industrial Acc. Com. (Harris) (1955) 44 Cal. 2d 604, 608, 20 Cal. Comp. Cases 114, 283 P.2d 1039]. Rather, the factors of disability or WPI from the prior disability are rated together with those from the subsequent industrial injury to produce the combined disability rating required by Labor Code section 4751.

**Pre-Existing Disability Discussion:** Please note that prior labor disabling disability is rated as it exists at the time of the subsequent industrial injury; and the apportionment statutes applicable in an industrial injury case do not establish prior labor disabling disability in an SIBTF case. However, the apportionment is important for the analysis of the combined degree of disability.

Thus it is important that in your discussion of pre-existing disability and its labor disabling nature please discuss the following issues:

- Whether an applicant have been “permanently partially disabled” at the time of a subsequent industrial injury and if yes, please indicate, which prior evidence show that non-industrial prior labor disabling disability had achieved permanency at the time of the subsequent industrial injury.

•Whether prior disability have impacted the applicant’s ability to work in a **demonstrable way**, and if yes - please describe whether these limitations resulted or could result for applicant in loss of wages, change in jobs, and/or change in work duties or abilities and other impact of the applicant’s ability to work.

**Discussion of Subsequent Industrial Injury:** Please note that per *Brown v. Workers*, a finding and award or a stipulated award is not necessary to prove the compensability of the industrial case, thus in SIBTF case your opinion about compensability of the subsequent injury is important.

Please note further, that for the purposes of SIBTF case, a C&R does not necessarily establish any fact in a case. C&R in the regular benefits case neither proves nor disproves compensability, nor does it prove any level of disability. Thus, you are expected to provide an impairment **rating within your specialty as of the date of the evaluation** and provide your opinion as to the apportionment to pre-existing conditions, subsequent industrial injury and post-subsequent industrial injury.

Finally, it is expected that you would provide your answer to the following important questions:

•Whether the degree of disability from prior disability and subsequent injury combined is greater than that from subsequent injury alone,  
*and*

•Whether subsequent compensable industrial injury resulting in additional permanent disability

In order to facilitate your evaluation, we provide medical records for the above applicant in our possession according to the exhibit list attached.

If you need any additional testing, please advise so.

If you believe that the applicant has health issues outside of your specialty, please defer these issued to the medical doctors of appropriate specialty, please indicate what specialty is recommended.

- 4) June 20, 2022, Attestation Pursuant to Cal Code Regs., Title 8, § 9793(n), Natalia Foley, Esq: I declare that the total page count of the documents provide to the physician is 6263 pages.

## **B - Review of Diagnostic Records**

- 1) April 19, 2018, MRI of the Cervical and Lumbar Spine, Vadim Tsesin, MD, Kaiser Permanente: Impression: Mild degenerative changes in the cervical spine producing



Re: Patient – SEERAM, Sandra  
Report Date – August 08, 2022  
Page 32

mild narrowing of the central spinal canal at C5-C6 and C6-C7. Findings slightly progressed since the prior exam. Mild degenerative changes in the lumbar spine without significant narrowing of the central spinal canal and neural foramina. Mild nonspecific prominence of the left jugulodigastric lymph node, unchanged since September 27, 2015, most likely benign finding.

- 2) January 29, 2019, X-Ray of Chest, Reza Habibi, MD, Kaiser Permanente: Impression: The lungs are clear. There is no evidence for consolidating pneumonia or pulmonary edema. There is no pleural effusion or pneumothorax. The heart and mediastinum are within normal limits. Osseous structure are grossly unremarkable.
- 3) January 30, 2019, Bilateral Mammo Screening Sequential with or without Computer Aided Detection Analysis, Steven Tran, MD, Kaiser Permanente: Impression: Negative.
- 4) March 06, 2019, MRI of Thoracic Spine without Contrast, Robert O. Lindsey, MD, Kaiser Permanente: Impression: Unremarkable MRI of the thoracic spine.
- 5) January 27, 2020, X-Ray of Chest, Alan Kaneshiro, MD, Kaiser Permanente: Impression: No significant abnormality.
- 6) May 14, 2020, US Neck Soft Tissue, Edward Kalinowski, MD, Kaiser Permanente: Impression: Small lymph node, stable.
- 7) August 25, 2020, CT Neck and Chest, Kaiser Permanente: Impression: 1) Mildly enlarged left juxta jugular (level **Ila**) cervical lymph node measuring up to 1.5 x 0.7 x 1.4 cm in addition to prominent left submandibular region (level **Ib**) lymph node measuring up to 1.6 x 0.7 x 0.8 cm are seen in the region of palpable concern within the left neck. 2) Multiple small pulmonary nodules measuring up to 4 mm in size are noted within the lungs bilaterally. Consider follow-up low-dose CT chest examination in 12 months to assess stability.

### **C - Review of All Other Records**

- 1) I reviewed the entire medical file with all pertinent patient information. I have reviewed my initial history, examination and medical file.
- 2) November 29, 2017, Office Visit, Helen Chung, MD, Kaiser Permanente: HPI: The patient has a history of prediabetes mellitus, hypothyroid, gastroesophageal reflux disease, vitamin D deficiency, and bilateral carpal tunnel syndrome. She presented with neck pain radiating to the arms with numbness and tingling associated with headaches. The symptoms were worse at work. She was a bank manager at Chase and she had a lot of stress. They had her travelling to Florida a lot, where she had to float around different branches. Physical Examination: Her mood appeared anxious. Diagnoses: 1) Cervical myofascial pain syndrome. 2) Cervical disc degeneration. 3) Chronic neck pain.

Treatment Plan: Referral - physical medicine; prescribed Cymbalta 20 mg, Robaxin 500 mg. Ketorolac Injection 30 mg; offered TPI: Deferred per patient preference.

- 3) February 16, 2018, Progress Note, Helen Chung, MD, Kaiser Permanente: Chief Complaint: Neck pain. History of Present Illness: At this time patient reported that her neck pain has improved with rest, off work, and medications. She requested a refill on Meloxicam. Current Medication: Meloxicam 15 mg, Topamax 25 mg, Cymbalta 20 mg, Lidoderm 5 % Top PTMD Patch, Robaxin 500 mg. Diagnoses: Cervical myofascial pain syndrome; chronic neck pain > 3 months; cervical disc degeneration. Treatment Plan: Meloxicam 15 mg; refill provided, again discussed GI precautions, and that other NSAIDS to be avoided while on Meloxicam. Continue Cymbalta 20 mg, Methocarbamol, and Topamax. Offered **TPI** but she declined. Continue HEP/ACP. Follow up with IPMP. Follow up with psych for anxiety/stress. **DMI**: Patient declined extension at this time.
- 4) March 23, 2018, Office Visit, Denise Hom, MD, Kaiser Permanente: Chief Complaints: Neck, shoulder and back pain as well as tingling of feet. **Illegible print.** Meloxicam, Methocarbamol, Cymbalta, and Topamax were prescribed. TPI was offered, but she declined. Continue home exercise program. She should follow up with IPMP and psych.
- 5) March 26, 2018, Progress Note, Helen Chung, MD, Kaiser Permanente: Chief Complaints: Chronic neck pain. History of Present Illness: Patient with history of pre DM, hypothyroid, GERD, vitamin D deficiency, and bilateral CTS presented for followup of her neck pain. Previously saw Dr. Nguyen PM&R for bilateral CTS, also previously saw Dr. Acord for neck pain. Last saw Dr. Chung on 02/18. Her neck pain was radiating to arms. Reports aggravation with work. She works as a bank manager for Chase. She specified that her symptoms flared with work travel to Florida and stress. Requested **DMI** to include no flying, and limit driving no more than 30 min/day. Current Medication: She was taking Meloxicam as needed occasionally. Reported that Topamax was helpful and Cymbalta as well. Tried Nortriptyline but stated “it knocked her out.” She was not taking Ibuprofen. Elavil 10 mg made hand numbness worse. Diagnoses: 1) Chronic neck pain. 2) Cervical myofascial pain syndrome. 3) Cervical disc degeneration. Treatment Plan: Continue Meloxicam/Methocarbamol, Cymbalta, and Topamax. She was offered TPI previously but she declined. Continue HEP/ACP. Follow up with IPMP full program. Follow up with psych for anxiety/stress. DMI provided. FMLA request: Referred to medical records.
- 6) April 11, 2018, Intake Visit (Medical Consultation) with Psychiatrist, Kevin Marsee, MD, Kaiser Permanente: Chief Complaint: Anxiety. History of Present Illness: The patient had intake here in December with Sayaka, and was referred to work health program, but didn't attend screening appointment. Per intake: depressive symptoms related to multiple stressors. Her depressive symptoms started in 2012 due to her boss who was “threatening and demanding.” She developed medical conditions, including severe headache, which made it difficult for her to function at work. She had been moving back and forth between Florida and California, but they decided to move to

California permanently 2 years ago. Her husband and two children moved to CA first, but she got stuck in Florida since she had not been able to find a job to transfer within Chase. This had caused some marital issues. She had been feeling overwhelmed by taking care of her elderly parents as well. She felt that her parents and siblings had been distancing themselves from her regardless of her efforts to support them, which also distressed her. Her depressive symptoms started getting worse since June 2017 due to increased troubles at work. She was experiencing severe somatic symptoms at work and decided to take a short-term disability and leave work. She was also prescribed with Cymbalta, which had been helping her tremendously. Her progress was reflected on today's TPI scores. She stated that her condition was a lot worse three weeks ago. She has long history of somatic/physical symptoms (e.g. Headaches, myofascial pain, various joint pains), followed by physical medicine for at least a few years, seen once by neurology in 2013 and determined to have unspecified paresthesias.

She had always been a worrier, usually about finances and the future (was also quite shy as a child), and had a history of muscle tension and other somatic complaints when she was under a lot of stress. Also had insomnia, irritability, restlessness when anxious and stressed. The somatic symptoms were most distressing for her, and were what had limited her ability to work recently. She had recently made the connection between stress/anxiety and her physical discomfort. No apparent history of major depression. Extensive review of symptoms did not reveal any evidence of a history of psychosis, mania, or PTSD. Current Medications: Topamax 25 mg, Cymbalta 20 mg, Norethindrone-E.Estradiol-Iron (Microgestin Fe 1/20, 28,) 1 Mg-20 Mcg (21)/75 Mg (7); Lovastatin 20 mg; Levothyroxine 88 mcg. Impression: Generalized anxiety disorder. Ruled out somatic symptom disorder. Treatment Plan: 1) Medication: Increased the Cymbalta as directed by Dr. Chung. It was reasonable for Dr. Chung to continue prescribing this medication, but she could contact Dr. Marsee with any questions. 2) Therapy/Education: The integrated pain management program had a weekly support group, run by clinical psychologist, Dr. Amanda Borgida, every Thursday at 3:30-4:30. Patient to call the pain management clinic to sign up for the group. Dr. Marsee would send a message to Virginia Coyle, the psychologist she talked to about the integrated pain management program. If the psychotherapy through IPMP was not adequate, she was to contact them and they could refer her for individual psychotherapy. 3) Substance use: It was important to avoid the use of heavy alcohol and illicit drugs, which could interact with medications, worsen psychiatric conditions, and have negative social and health consequences. 4) Medical: Continue to see her primary care provider. If she did not yet have a primary care provider, was to sign up for one and set up an appointment for routine health maintenance.

- 7) January 28, 2019, ED Note, Elezer A Negus, MD, Kaiser Permanente: Chief Complaint: Left sided neck/arm pain with weakness and swelling. History of Present Illness: The patient is brought in by EMS from work. She is here for left sided weakness and swelling x today. She has a history of cervical spondylosis here complaining of left arm pain and discomfort with some weakness since this morning. She states no numbness, weakness now resolved; but felt diffuse tightness and pain. She was at work, and has been under

some stress lately. Not sleeping well. Complaining of pulling sensation from back of neck to left arm/hand area. Orders Placed in the ED: 1) X-ray of chest. 2) Labs. 3) Initiate cardiac monitoring. 4) EKG 12 or more leads with interpretation & report. Assessment: 1) Neck pain. Plan: She is reassured that, at this time, these symptoms do not appear to represent a serious or threatening condition. She is discharge home. Follow-up with PCP. Continue previously prescribed medications as directed.

- 8) January 30, 2019, ED Followup Note, Denise Hom, MD, Kaiser Permanente: Reason for Visit: ER followup – 01/28/19. History of Present Illness: The patient presented for follow up of left hand numbness, chest tightness, neck swelling (pushing forward on neck). She was driving for an hour and 10 minutes in traffic. She could barely swallow and took Cymbalta (x 2) and 1 Aspirin. She felt terrible. She had transferred job since January 14, but drives 3 hours in total. She had no time for acupuncture and would consider chiropractic treatment. PE: Ht: 5'4." Wt: 63.6 kg. BMI: 24.07. Diagnoses: 1) Follow up after ED visit. 2) Cervical spondylosis. 3) Cervical myofascial pain syndrome. 4) Chronic neck pain > 3 months. 5) Mixed hyperlipidemia. 6) Hypothyroidism due to thyroiditis. 7) Costochondritis. 8) Acute stress disorder. 9) Right carpal tunnel syndrome. 10) Paresthesia of upper limb. 11) Numbness and tingling of skin. 12) Mixed hyperlipidemia. 13) Hypothyroidism due to thyroiditis. 14) Prediabetes. 15) Upper respiratory infection. 16) Left lower quadrant abdominal pain. 17) Vitamin D deficiency. 18) GERD. 19) Contraceptive management menorrhagia. 20) Eczema. 21) Hyperpigmentation of skin. 22) Congenital keratosis pilaris. 21) Alopecia. 22) Foot callus. Plan: She was recommended Guaifenesin 10-100 mg/5 mL and Retin-a 0.01% top gel. She was to switch Mobic with Motrin. She was to continue Topamax, Cymbalta, Lidoderm patch, Robaxin, wristband, Lovastatin 20 mg, and Levothroid 88 mcg, Calcium + Vitamin D, Pepcid, and Protopic. She was to follow up with PMR. Neurology, ob/gyn, dermatology, and podiatry. She was to follow up in 3-6 months.
- 9) February 27, 2019, Progress Note, Tony Truong, MD, Kaiser Permanente: Chief Complaints: Bilateral hand numbness/tingling. History of Present Illness: The patient presents with neck pain, left arm pain, bilateral hand numbness, tingling and discomfort. Assessment: 1) Numbness and tingling of skin. 2) Bilateral carpal tunnel syndrome. Discussion: Symptoms likely multifactorial with possible attribution to stress. Prior EMG/NCS in 2015 with mild bilateral carpal tunnel syndrome. Minimal carpal tunnel syndrome symptoms at this time. Discussed considering trial carpal tunnel corticosteroid injection for diagnostic and therapeutic purposes, which she deferred at this time. Follow up with PMR, Dr. Chung with MRI thoracic spine. Consider neuro consultation. Treatment Plan: 1) Night splint. 2) Corticosteroid injection. 3) Carpal tunnel release. Follow up as needed, for corticosteroid injection. Follow up with PMR, and PCP as needed.
- 10) March 14, 2019, Progress Notes, Denise Hom, MD, Kaiser Permanente: Subjective Complaints: The patient presented for annual physical examination. She reports that she wakes up with headaches. Objective Findings: BP: 96/54. Wt: 139 lbs. Noted decreased ROM cervical spine with tenderness to the bilateral trapezius. Assessment: 1)

Routine adult health check-up examination. 2) Cervical spondylosis/myofascial pain syndrome. 3) Chronic neck pain for more than 3 months. 4) Costochondritis. 5) Numbness and tingling of skin, bilateral feet. 6) Back pain. 7) Acute stress disorder. 8) Right carpal tunnel syndrome. 9) Numbness and tingling of skin, right side of face. 10) Mixed hyperlipidemia. 11) Hypothyroidism due to thyroiditis. 12) Prediabetes. 13) Vitamin D deficiency. 14) GERD. 15) Menorrhagia. 16) Eczema. 17) Hyperpigmentation of skin. 18) Congenital keratosis pilaris. 19) Alopecia. 20) Foot callus. Plan: Laboratory studies. Tdap vaccination.

- 11) August 27, 2019, Outpatient Initial Adult Diagnostic Evaluation, Allison Altwer, MFT, Kaiser Permanente: HPI: The patient was seeking therapy services due to being referred by her pain management practitioner, who informed her that her physical pain might be tied to her anxiety level. She had been experiencing anxiety since 2017 when a new supervisor was hired at her work, who was verbally abusive, unsupportive, harassing her, and discriminating against her. She had gone to HR numerous times to resolve concerns, but HR had not taken action. She reported her anxiety symptoms as constant worry, rumination, racing thoughts, racing heart, panic symptoms, crying spells, hot flashes, anger, poor focus, irritability, confusion, headaches, tingling in fingers/feet, nausea, stomach pain, muscle tension, weight gain/overeating, etc. This stress was causing her performance to decrease at work, which had led to her missing bonuses and corrective action. She called out of work often and she had now been on disability since March 2019. She was at risk to lose her job. She could not drive for more than 15 minutes without starting to feel panic. This had caused financial stress on family and her children and husband sometimes resented her for it. This had led to more strained relationships in the home. Her physical health had deteriorated and she saw doctors for numerous health issues related to stress. Her social life had been negatively affected because she isolated herself and she had not been keeping up relationships. She had just recently realized that her physical health was tied to her stress and she would like therapy at this time to deal with the stress. DSM 5 Symptom Evaluation: She had symptoms of depression with irritable mood, feeling worthless, decreased sleep, psychomotor agitation, increased appetite, weight gain, decreased concentration, decreased energy/fatigue, feeling hopeless, low self-esteem, and tearfulness. She had symptoms of anxiety/panic with excessive worry or anxiety, difficulty controlling the worry, restlessness, feeling keyed up or on edge, easily fatigued, difficulty concentrating, mind going blank, irritability, muscle tension, and sleep disturbance Individual therapy was discussed with external provider and medication evaluation due to her reports of wanting to discuss her current Cymbalta prescription with a psychiatrist. She agreed to treatment. Treatment Interventions Used in Session: Diagnostic intake interview including assessment of symptoms, strengths/resources, risks and psychosocial and environmental challenges, insight- oriented, supportive therapy and empathetic listening.
- 12) September 12, 2019, PT Treatment Summary, Alice Langit-Cole, RPT, Kaiser Permanente: The patient attended PT sessions from 07/31/19 to 09/12/19. She received treatment modalities that included therapeutic exercises.

- 13) September 13, 2019, Initial Psychiatry Evaluation, Mahlet Dori Girma, MD, Kaiser Permanente: Chief Complaint: Anxiety. DSM-5 Diagnoses: 1) Generalized anxiety disorder. 2) Depressive disorder, other specified. Treatment Plan: 1) Psychiatric: Increase Cymbalta to 90 mg for anxiety and mood. 2) Psychosocial: Recommend individual psychotherapy and group psychotherapy for anxiety (CBT for anxiety/depression or Panic/Anxiety group or Anxiety group in vivo exposure). 3) Medical: Recommend light exercise as tolerated. 4) Work/School: Continue time off for now, also recommended discussing work related issues with her HR department. Follow up: Return to the clinic in 4 weeks or sooner if needed.
- 14) October 07, 2019, Primary Treating Physician's Progress Report, Thomas Curtis, MD: DOI: CT: 11/06/2018 - 05/02/2019. Subjective Complaints: The patient had continued symptoms of both anxiety and depression. Objective Findings: She had continued objective functional improvement. Diagnoses: 1) Major depressive disorder, single episode. 2) Generalized anxiety disorder. 3) Psychological factors affecting medical condition (stress-intensified headache, neck/shoulder/low back tension/pain, nausea, chest pain, shortness of breath constipation, abdominal pain/cramping, diarrhea and possible stress-aggravated high blood pressure). Treatment Plan: Psychiatric medication, CBT psychotherapy; all as needed and all as requested by RFA in effect according to guidelines. Work Status: Off work. Required a medical leave of absence from 10/07/19 to 01/07/20. She was found to be temporarily totally disabled on a combined physical and psychological basis.
- 15) October 11, 2019, Psychiatric Progress Notes, Mahlet Dori Girma, MD, Kaiser Permanente: Chief Complaint: Anxiety. DSM-5 Diagnoses: 1) Generalized anxiety disorder. Treatment Plan: 1) Psychiatric: Increase Cymbalta to 120 mg; however, she would prefer to wait until her pain management doctor weans her off of Topamax. For now continue Cymbalta 90 mg. 2) Psychosocial: Start individual and group psychotherapy for anxiety (recommended Work Health Program or Panic and Anxiety group). Consider resources thorough Center for Healthy Living at KP (wellness coaching for stress management, sleep workshops). 3) Medical: Taper Topamax per pain management recommendations. Recommended exercise as tolerated. 4) Work/School: Off work note provided given severity of symptoms. Follow up: Return to the clinic in 4-6 weeks or sooner if needed.
- 16) November 14, 2019, Psychiatric Progress Notes, Mahlet Dori Girma, MD, Kaiser Permanente: Chief Complaint: Anxiety. DSM-5 Diagnoses: 1) Generalized anxiety disorder. Treatment Plan: 1) Psychiatric: Continue Cymbalta but split dose into 30 mg in the morning, and 60 mg in the evening to reduce GI distress. Can use Klonopin 0.25-0.5 mg (1/2 tablet or up to 1 tablet) as needed for severe anxiety. Advised not to combine with any opiates, alcohol or other substances. Recommended to follow up with staff regarding starting individual therapy and/or group therapy. Also recommended some CBT strategies including exposures. Center for Healthy Living at KP (wellness coaching for stress management sleep workshops). 2) Medical: Recommend exercise as tolerated.

Re: Patient – SEERAM, Sandra  
Report Date – August 08, 2022  
Page 38

Follow up with PCP as needed. 3) Followup: Return to the clinic in 4-6 weeks or sooner if needed.

17) November 26, 2019, Telephonic Appointment Visit (TAV), Denise Hom, MD, Kaiser Permanente: Reason for TAV: Telecare. Call Documentation: The patient has on/off days; followup with psyche – on longer term disability now. Followup with PMR for pain. She reports that she has ran out of Lovastatin. Labs were pending. Other symptom includes itchy rash over the arms/shoulders. Just happened; will send pictures. Assessment: 1) Generalized anxiety disorder. 2) Cervical spondylosis. 3) Chronic neck pain > 3 months. Plan: As noted above, followup with psyche, PMR, and pain management as needed. Check labs. Followup as needed.

18) December 11, 2019, Pain Management Followup Visit, Mobashshera Jabeen, PA, Kaiser Permanente: Reason for Consult/Chief Complaint: Neck and joints pain. History of Present Illness: The patient presents with neck and joints pain since 2012. She reports that the pain started gradually due to work related stress. There was increased work load. The pain was radiating to both upper extremity and lower extremity with numbness, tingling, weakness on and off. She reports that the neck pain is feeling better and is feeling less stressed. She is on long term disability for 2 years. She reports she wants to get better before go back to work. She reports she is trying to eat healthy and follow up all her medical recommendations. Frequency: Every day. Quality: Aching, stabbing, sharp, throbbing. Severity: 7-10/10, Today: 6/10. Symptoms have been progressively worsening. Aggravated by: Walking, exercise, standing, sitting, activity. Prior pain interventions: Physical Therapy - did not help. Acupuncture - helped pain. Current Pain Medication: Meloxicam (Mobic) 15 mg, Robaxin 500 mg, Cymbalta 30 mg, Topamax 100 mg. Pain Medications Tried: Motrin - helped to reduce pain better than Meloxicam. Diagnostic Studies: 04/24/18 dated MRI of cervical/lumbar spine revealed: Mild degenerative changes in the cervical spine producing mild narrowing of the central spinal canal at C5-C6 and C6-7. Findings slightly progressed since the prior exam. Mild degenerative changes in the lumbar spine without significant narrowing of the central spinal canal and neural foramina. Mild nonspecific prominence of the left jugulodigastric lymph node unchanged since September 27, 2015, most likely benign finding. Also reviewed the thoracic MRI dated 03/06/19, which did not reveal any abnormal findings. Assessment: 1) Cervical spondylosis. 2) Chronic neck pain > 3 months.

Discussion/Plan: No orders of the defined types were placed in this encounter. The patient presents with neck and joints pain. Advised importance of therapeutic exercise for strength and improve function. Advised to follow-up with physical therapy for stretching and strengthening. Informed her that pharmacotherapies are only one component of pain management and stressed importance of CBTR, PT and therapeutic exercise. Recommended chronic pain management without opioids. Discussed opioid medication indication, limitations and long-term adverse effects of including tolerance, physical dependence, withdrawal, hyper analgesia, depression, mood effects, hormonal changes including hypogonadism and osteoporosis, tooth decay. Advised to avoid opioid with other central nervous system depressants such as alcohol, Benzodiazepines, illicit

drugs, or sleep aids, because of the risk of overdose and death. Discussed pain medication advised not to take more medication than prescribed. Advised to limit Acetaminophen (Tylenol) use and not to exceed more than 3000 mg a day. Refilled Mobic 15 mg as needed for pain not more than 1 tablet a day with food. Avoid prolonged use as it may affect kidney. Continue Robaxin 500 mg, Cymbalta 30 mg, and Topamax 100 mg. Follow up for Physical Therapy with Alice Langit-Cole at IPMP. Follow up with Cognitive Behavior Therapy classes. Follow up with Dr. Coyle, Pain Psychologist for Psycho-social evaluation at IPMP. Follow up Acupuncture. Schedule with Trigger Point Injection with me as needed for upper back pain. Follow up TAV in 6 weeks to review pain medication.

- 19) December 19, 2019, Primary Treating Physician's Record Review Report, Thomas Curtis, MD/Gayle K. Windman, MD: DOI: CT: 11/16/18-05/02/2019. Review of Records: Reviewed Dr. Iseke's report dated 07/10/19. Discussion: The reports of Dr. Iseke confirmed the physical aspects of injury with diagnoses of radiculopathy, cervical region; other cervical disc displacement, unspecified cervical region; cervicgia; spinal enthesopathy, cervical region; pain in thoracic spine; hemangioma of skin and subcutaneous tissue; unspecified sprain of right wrist, initial encounter; unspecified mononeuropathy of right upper limb; unspecified sprain of left wrist, initial encounter; pain in left wrist; pain in hand and fingers; pain in left hand; reaction to severe stress, and adjustment disorders; chronic pain due to trauma; myositis, unspecified; and contracture of muscle, unspecified site. The doctor noted the patient's reaction to severe stress and adjustment disorders. She also had a stress case. On October 07, 2019, she was found to be too beset by stress-aggravated pain and disability, too beset by stress aggravated medical symptoms, and too depressed and anxious to work. She was observed to become emotionally unstable and disturbed at the contemplation of an immediate return to work. If she attempted to return to work, her emotional condition would deteriorate into worsened emotional dysfunction. She was found to be temporarily totally disabled on a combined physical and psychological basis. There would be no change in any of the previously expressed opinions. The particulars of disability would be the same as those described in the last report. There would be further reports to follow on an as-needed basis.
- 20) December 20, 2019, Psychiatric Progress Notes, Mahlet Dori Girma, MD, Kaiser Permanente: Chief Complaint: Anxiety. DSM-5 Diagnoses: 1) Generalized anxiety disorder. Treatment Plan: 1) Psychiatric Medications: Cymbalta: Increase dose to 100 mg daily (advised using higher dose of 60 mg every morning, and lower dose of 40 mg every evening for anxiety/pain). Klonopin: Reduce dose to 0.125 mg up to 2 times daily as needed for severe anxiety. 2) Therapy/Services: Start individual therapy and continue work health program. Discussed services for patient. 3) Medical: Recommend exercise as tolerated. Follow up with PCP as needed. 4) Work/School: Note/letter provided. 5) Follow up: Return to the clinic in 6-8 weeks or next available appointment.
- 21) January 08, 2020, Primary Treating Physician's Permanent and Stationary Medical-Legal Report, Harold Iseke, DC: DOI: CT: 05/17/2018-05/18/2019. HPI: The patient states



that while employed with JP Morgan Chase, she sustained injuries on a cumulative trauma basis from 05/17/2018-05/18/2019. She sustained injuries to her cervical spine, thoracic spine, bilateral wrist and hands and bilateral knees. She was referred here for evaluation and treatment. She has had 19 chiropractic visits to date and 22 acupuncture session to date. Total number of treatments: 41. Having completed the regimen of treatment, she has reached maximum medical improvement and is ready for permanent and stationary considerations. Subjective Complaints: Head: The patient complained of activity dependent temporal to frequent to constant achy, sharp, throbbing headache radiating to head with blurred vision and light sensitivity. Her pain was exacerbated with stress, activity, and prolonged work. Cervical spine: She complained of constant moderate achy neck pain and stiffness becoming severe pain radiating to the right arm with numbness and tingling with sudden or repetitive movement, lifting 10 pounds, looking up, looking down, twisting and flexing, and extending especially on a computer. Thoracic Spine: She also complained of constant mild upper/mid back pain and stiffness becoming sharp moderate pain with sudden or repetitive movement, lifting 10 pounds, sitting, walking, bending, and twisting. Right wrist: She complained of activity-dependent moderate sharp, stabbing right wrist pain, stiffness and numbness, associated with reaching, grabbing/grasping, gripping, squeezing, pushing, and pulling repetitively.

Left wrist: She complained of activity dependent moderate sharp, stabbing left wrist pain, stiffness, and numbness, associated with reaching, grabbing/grasping, gripping, squeezing, pushing, and pulling repetitively. Right hand: She complained of activity-dependent moderate sharp, stabbing right-hand pain, stiffness, and numbness, associated with reaching, grabbing/grasping, gripping, squeezing, pushing, and pulling repetitively. Left hand: She complained of activity dependent moderate sharp, stabbing left-hand pain and stiffness, associated with reaching, grabbing/grasping, gripping, squeezing, pushing, and pulling repetitively. Right knee: She complained of activity-dependent moderate right knee pain and stiffness, associated with sudden or repetitive movement, lifting 10 pounds, standing, walking, bending, kneeling, twisting, and squatting. Left Knee: She complained of activity dependent mild left knee pain and stiffness, associated with sudden or repetitive movement, lifting 10 pounds, standing, walking, bending, kneeling, twisting, and squatting. PE: Ht: 5'4½. Wt: 125 lbs. Blood Pressure: 98/78. Diagnoses: 1) Radiculopathy, cervical region. 2) Other cervical disc displacements, unspecified cervical region. 2) Cervicalgia. 3) Spinal enthesopathy, cervical region. 4) Pain in the thoracic spine. 5) Spinal enthesopathy, thoracic region. 6) Hemangioma of skin and subcutaneous tissue. 7) Unspecified sprain of right wrist, initial encounter. 8) Unspecified mononeuropathy of right upper limb. 9) Unspecified sprain of left wrist, initial encounter. 10) Pain in left wrist. 11) Pain in hand and fingers. 12) Pain in left hand.

13) Reaction to severe stress, and adjustment disorders. 14) Major depressive disorder, single episode, unspecified. 15) Anxiety disorder, unspecified. 16) Irritability and anger. 17) Chronic pain due to trauma. 18) Myositis, unspecified. 19) Contracture of muscle, unspecified site. Discussion: The patient claims work-related injury she sustained on a continuous trauma basis from 05/17/2018-05/18/2019 while performing her usual and

customary job duties at JP Morgan Chase. She stated that while performing her usual and customary work duties on the above noted date she injured her cervical spine, thoracic spine, bilateral wrist and hands and bilateral knees. Impairment Rating: Cervical spine: 8% WPI. Thoracic spine: 5% WPI. Right knee: 4% WPI. Left knee: 4% WPI. Causation: The patient's current symptomatology is a result of continuous trauma 05/17/2018-05/18/2019 while performing her usual and customary job duties at JP Morgan Chase. Apportionment: Apportionment is not an issue. Work Restrictions: She is precluded from repetitive neck movements or prolonged fixed position of the neck. No repetitive bending, stooping, kneeling and squatting. Future Medical Care: Chiropractic and acupuncture treatment during the periods of exacerbation. Pain management for pharmacological management and possible epidural injection to the cervical spine and corticosteroid injection to the bilateral wrist and bilateral knees. If no relief, then patient should also have access to orthopedic surgeon for further treatment recommendations. She should also have access to a psychologist for anxiety and depression issues.

22) January 10, 2020 (DOE), March 31, 2020 (DOR), Primary Treating Physician's Permanent and Stationary Report with Psychological Test Results, Thomas A. Curtis, MD; DOI: CT: 11/16/18-05/02/19. Identifying Data: An Application for Adjudication of Claim for Workers' Compensation Benefits citing a cumulative trauma date of injury from 11/16/2018 to 05/02/2019 involving her stress and psyche. It would appear that the patient's claim has become denied. There was a letter dated 09/23/2019 submitted by the applicant attorney, Natalia Foley, Esq., referring her to Dr. Thomas Curtis for psychological evaluation and treatment. Dr. Curtis was designated as the primary treating physician. Further treatment may be required on an as-needed basis. However, an estimate of permanent and stationary residuals can now be made. This report would comprise her comprehensive permanent and stationary psychological evaluation. Dr. Curtis requested for all the relevant missing medical records of this case. This request would be ongoing for new documents. Identifying Data: The patient completed her associate's degree. She identifies as Hindu. She currently lives in Torrance with her husband, Vijay (51), her son, Kamron (22) and her daughter Karina (16). History of the Work Injury: She began her employment at JP Morgan Chase Bank on 12/27/1988. Her last day of work there was on 03/15/2019. She was placed on disability by Dr. Helen Chung, a physical medicine specialist. As a branch manager, her job duties included managing employees, customer experience and sales, counting cash, conducting audits and daily meetings and opening and closing the bank. She received average written work performance work evaluations. For her good work, she also received bonuses and raises in pay. She described disturbing experiences of stress at work. After she became transferred to another branch in May 2018, the market director, Kathy, promised her help. She was overwhelmed. She opened new accounts, safe deposit boxes and performed teller work. There was repetitive ladder climbing and the pulling out of the safe deposit boxes. She also audited cash including the lifting and counting of heavy coins.

She did everyone else's job duties. She also described harassment by Kathy, who frequently singled her out during conference calls and meetings. Kathy questioned why the patient did certain things. She micromanaged the patient in front of her coworkers

and compared her branch to other, high performing branches with sufficient staff. This was an unfair comparison. She worked about ten hours a day. There were further stressors. In January 2019, she was transferred again. The new location was under performing. Before too long, the performance level of the branch had increased. They completed a renovation of the bank as well. She was very busy with all of this. She had no time for lunch. She also had to care for her children. The branch located at Fairfax was far from her home. She asked Kathy to find a branch closer to her home. On one occasion, she experienced chest tightness and headaches. She had difficulty standing and walking, and 911 was called. She was transported to Kaiser at Cadillac. She underwent extensive blood work and an EKG. She was placed off work for one week. The problems persisted. Kathy made weekly bank visits. On one occasion, Kathy arrived with a pre-auditor. Kathy then yelled and screamed at the patient because her monitor did not have a privacy screen protector. Kathy told her that she could not pass an audit. The patient was humiliated in front of her staff. This was uncalled for the patient had passed many audits. There was also physical trauma, which adversely influenced the emotional complications of her work stress. She developed the onset of pain in her neck, wrists and hands in 2017. She continued to work with increased pain. She consulted with her doctor at Kaiser. An MRI was taken of her neck, which revealed disc damage. The patient was referred to Harold Iseke, D.C. She was unable to perform her usual job duties. She took an intermediate leave of absence.

Interim History: Since the prior evaluation at this office, the patient received five CBT sessions 11/05/2019 to the present and continuing with Gilda Ruelas, MFT. There has also been the provision of psychotropic medications including Cymbalta, Celexa and Clonazepam. The treatment has been directed towards the relief not only of anxiety, depression and sleep disruption, but also to the reduction of multiple stress-related medical complaints. As indicated below, the treatment has been beneficial. She reported improvements in depression and anxiety. She reported improvements in her social functioning. She has been better able to communicate effectively with people because she has felt less irritable and angry. There has been increased interest in daily activities such as dressing appropriately. She has felt less tired during the day. There have also been improvements in her ability to maintain her attention on a movie. Since the prior evaluation at this office, she has remained unable to work, primarily because of her anxiety caused by the multiple inherent stressors, the work overload, being humiliated by the market director and generally undermined and being transferred around. There was also favoritism with a clique such that the market director, Kathy, replaced the patient as manager of the Beverly LA branch with her friend. The patient was subjected to unfair criticisms and inappropriate blame for understaffing. There were multiple managers who quit because of Kathy, a known difficult and essentially incompetent director who had become bitter in her demotion. In the end, she became stressed out to the point of nervous breakdown and panic attacks resulting in an ER hospitalization at Kaiser. Due to the persistent stress-intensified medical symptoms, the patient will be referred to an internist. Dr. Iseke will address her orthopedic complaints. Despite the passage of time and the input of treatment, there has been the persistence of significant emotional

complications. No amount of emotional treatment could reasonably be expected to completely erase the adverse impact and complications of her work injuries.

Any improvement of symptoms would now be expected to occur, if at all, at a slower rate over a more prolonged period of time. Therefore, in consideration of all relevant factors, the psychological condition can be considered as stabilizing into permanent and stationary status for practical rating purposes. She has remained symptomatic. Her emotional condition will be described in more detail below. Applicant's Report of Emotional Symptoms: She reported persistent depressive mood plus symptoms including changes in appetite, decreased interest and motivation, insomnia, decreased energy, difficulty thinking and feelings of inadequacy. She experienced recurring periods of anxiety with symptoms including recurrent panic attacks, excessive worry, difficulty controlling her worry, feelings of restlessness, feeling "keyed up" and on edge, difficulty concentrating, irritability, muscle tension, abdominal distress, feelings of terror, fear of dying, derealization, feeling like she is choking, jumpiness and feeling pressured. There were unprovoked crying episodes that occurred multiple times per week. She experienced stress-intensified medical symptoms with worsened headache, neck/shoulder/back muscle tension/pain, nausea, chest pain, shortness of breath, palpitations, constipation and abdominal pain/cramping. Due to her mental disorder, she experienced impairment in her daily activities including her personal hygiene, bodily functions, eating properly, sleeping effectively and functioning sexually. There were problems with stress-related constipation and diarrhea. There were problems with stress-related constipation and diarrhea. She experienced a depressively decreased interest in her basic self-care activities including brushing her teeth, combing her hair and dressing appropriately. In addition, there was decreased motivation to perform normal housekeeping activities including making the bed, cooking a meal, doing the dishes and vacuuming the home. She developed decreased sexual interest due to depression, anxiety, emotional withdrawal, irritability and anger.

She developed difficulty falling and staying asleep due to depression, anxiety and worry. Because of her insomnia, she experienced morning headaches, trouble concentrating and a change in her personality. Due to her emotional distress, she had difficulty interacting appropriately with others including family members, friends and neighbors. She became emotionally withdrawn. Due to her mental disorder, she developed attitudes that impaired her ability to socialize including guardedness, defensiveness, mistrustfulness and suspiciousness. She became irritable and impatient with people. There were problems with becoming short-tempered and being prone to inappropriate angry outbursts. She experienced difficulty tolerating prolonged contact with people because of her stress-intensified pain, depression, anxiety, irritability, emotional withdrawal and anger. There was insufficient emotional control such that the patient yelled at others. Because of her emotional disturbances, there was difficulty paying attention, concentrating and remembering things. She experienced problems with distractibility, slowed thinking, mental confusion, mental blocking and loss of her train of thought. Because of her cognitive impairment, she had difficulty communicating her thoughts. Her cognitive functioning became impaired such that there was difficulty in her ability to

read a magazine or book and follow the plot of a movie or TV shows. She also had problems remembering where she left things around the house, telephone numbers, appointments and birthdays, directions and what people told her. Due to her depression and anxiety, there was psychological fatigue and energy depletion. Work History: She was employed by JP Morgan Chase Bank as a branch manager from about 12/27/1988 to 03/15/2019. Prior Work Injuries: She reported other work injuries. She reported that she experienced bank robberies while at JP Morgan Chase Bank in 1989, 1993, 2003 and 2007.

There were no claims filed. As a result of these robberies, she has continued to feel unsafe at JP Morgan Chase Bank. She reported that she filed a stress case in 2012. As well, in 2012, she injured her neck, back and knees due to heavy lifting. She has not yet recovered from these injuries. Any associated records should be reviewed. Medical History: She reported she was diagnosed with migraine headaches in 11/2017. She also indicated that she was diagnosed with hypothyroidism. In regard to medication usage, she has recently taken Levothroid, Cymbalta, Meloxicam, Robaxin, Topamax. Medical Record Review: Dr. Curtis reviewed the Dr. Iseke's initial report dated 07/10/19. Discussion: The reports of Dr. Iseke confirmed the physical aspects of injury with diagnoses set forth as follows: radiculopathy, cervical region; other cervical disc displacement, unspecified cervical region; cervicgia; spinal enthesopathy, cervical region; pain in thoracic spine; hemangioma of skin and subcutaneous tissue; unspecified sprain of right wrist, initial encounter; unspecified mononeuropathy of right upper limb; unspecified sprain of left wrist, initial encounter; pain in left wrist; pain in hand and fingers; pain in left hand; reaction to severe stress, and adjustment disorders; chronic pain due to trauma; myositis, unspecified; and contracture of muscle, unspecified site. The doctor did note her reaction to severe stress and adjustment disorders. Diagnoses: 1) Major depressive disorder, single episode. 2) Generalized anxiety disorder. 3) Psychological factors affecting other medical conditions (stress-intensified headache, neck/shoulder/back muscle tension/pain, nausea, chest pain, shortness of breath, palpitations, constipation and abdominal pain/cramping). GAF = 50 (current). [Symptoms cause serious impairment in social and occupational functioning to the point of being unable to hold a job at present].

Disability Status: It would appear from the history and examination that she has been temporarily totally disabled on an emotional basis from her last day of work at JP Morgan Chase Bank on about 03/15/2019 to the present and continuing, hopefully until her condition becomes more stabilized in the near future. Impairment Rating: WPI of 30% (GAF - 50). Causation/Apportionment: It was observed that the patient's symptoms of psychiatric injury were visibly connected to the causative events within her work at JP Morgan Chase Bank. The actual events of employment were predominant as to all causes combined, the work-related causes constituting greater than 50% of all of the causal factors, in this patient's case, 100% industrial as explained below. Of the 100% industrial psyche causation, about 60% would be attributed to the disturbing events at work described above, with only 40% attributed to the underlying impairment caused by the pain and disability in and of itself absent the industrial stress-aggravated muscle

tension pain and increased pain perception due to industrial depression. Future Care: Future psychological treatment benefits would be recommended. It may be useful for practical settlement purposes to estimate the amount of future treatment benefits following the settlement of the current Workers' Compensation matter. It would be recommended that the provision of approximately one year of weekly supportive psychotherapy sessions be set aside for her to be utilized intermittently as needed for the rest of her life to help relieve flare-ups of the emotional pain and suffering and the reduced psychological coping ability caused by the industrial injury to her psyche. She should also be provided with her psychotropic medications to be set aside for another year. The amount of necessary treatment could extend beyond the aforementioned estimate proffered for practical settlement purposes. It would be best for her to be provided with an open-ended future psychological treatment award. There will be further reports to follow on an as-needed basis.

- 23) January 27, 2020, Office Visit, Parker Warren Greene, PA, Kaiser Permanente: Chief Complaint: Right shoulder pain. HPI: The patient complains of right sided chest pain radiating through her shoulder to her back x 4 days, no history of same, no associated trauma, no upper respiratory infection signs and symptoms. Assessment: Musculoskeletal pain (primary encounter diagnosis). Note: Would get EKG (EKG rate of 83 no ST changes)/chest x-ray (negative), though likely musculoskeletal pain. Continue medications as prescribed and followup as needed. Plan: EKG 12 or more leads with interpretation & report. X-ray of chest. Prescribed Cyclobenzaprine 5 mg and Naproxen 500 mg.
- 24) February 14, 2020, Psychiatric Progress Notes, Mahlet Dori Girma, MD, Kaiser Permanente: Chief Complaints: Anxiety, depression. DSM-5 Diagnosis: 1) Generalized anxiety disorder. Treatment Plan: 1) Psychiatric Medications: Continue Cymbalta 100 mg daily. Continue Klonopin 0.125 mg on an as needed basis (up to twice a day). 2) Therapy: Continue individual therapy. Continue Work Health Program. 3) Other Resources: Center for Healthy Living (telephone wellness coaching for stress management, sleep workshops). 4) Medical: Follow up with PCP as needed. 5) Follow up: Return in approximately 3 months.
- 25) March 04, 2020, Psychiatric Progress Notes, Mahlet Dori Girma, MD, Kaiser Permanente: Chief Complaints: Anxiety, depression. DSM-5 Diagnosis: 1) Generalized anxiety disorder. Treatment Plan: 1) Psychiatric Medications: Continue Cymbalta 100 mg daily. Continue Klonopin 0.125 mg on an as needed basis (up to twice a day). 2) Therapy: Continue individual therapy. Continue Work Health Program. 3) Other Resources: Center for Healthy Living (telephone wellness coaching for stress management, sleep workshops). 4) Medical: Follow up with PCP as needed. 5) Follow up: Return in approximately 3 months.
- 26) March 09, 2020, Office Visit – Dermatology, Paola G. Rodriguez, MD, Kaiser Permanente: Reason for Visit: Referral (reason – patient with possible contact dermatitis, tried recommendations from virtual dermatology visit on 12/03/19; hair loss

(crown of scalp); skin lesion (around the neck). Subjective Complaints: 1) She is referred for rash on the upper arms, but has two other concerns as well. She says that for years she has had bumps and discoloration on the upper arms and now started on the back as well. She says it started with bumps, but admits that she tends to scratch and scrub in these areas; however, she denies pruritus. She has tried various topical steroids without improvement. 2) Hair loss in the scalp over the last couple of years: She has a history of hypothyroidism due to thyroiditis, but her TSH has been normal recently. She has noticed the thinning especially at the crown of the scalp. She has not tried any treatment. 3) Bumps on the neck and axilla that are bothersome. Sometimes they catch on things. Would like them removed. Assessment/Plan: 1) Lichen simplex chronicus: Upper arms and upper back. Hard to know if it started with a true dermatitis or possibly keratosis pilaris (noted on exam in 2011). Also, less likely lichenoid amyloidosis. Discussed diagnosis, prognosis, and treatment options and emphasized importance of minimizing friction and rubbing. No loofah and try to stop scratching. Start Carmol 40% topical cream. 2) Alopecia: Favor androgenetic alopecia (also noted in chart in 2014). Not likely related to hypothyroidism or low vitamin D, but can consider checking again in the future. Recommend starting Minoxidil 5% solution daily to twice a day x 4-6 months, at least. 3) Skin tag: Axilla and neck and numerous. Small seborrheic keratoses on the neck. Discussed diagnosis, prognosis, and treatment options and patient reassured. Did not have time for treatment of many snip excision of lesion at the right axilla after injection with 1% lidocaine with epinephrine. Hemostasis achieved with Drysol. She tolerated procedure well. Liquid nitrogen applied for 1 freeze/thaw cycle to 1 lesion at the right axilla. Mild erythema was noted and patient was advised on aftercare. Followup as needed.

- 27) March 23, 2020, Telephonic Appointment Visit, Helen Chung, MD, Kaiser Permanente: Chief Complaint: Low back/neck pain (last seen on 07/29/19). Assessment: 1) Chronic pain syndrome. 2) Anxiety. 3) Myofascial pain. 4) Cervical disc degeneration. 5) Lumbar spondylosis. 6) Bilateral carpal tunnel syndrome. Plan: The patient was on Cymbalta, Flexeril, Klonopin, and Naproxen. Followup IPMP pending. Continue ACP. She was referred to allergy department. Followup with psych for anxiety/depression/stress. She has Long Term Disability. She has followup US neck pending per PCP.
- 28) March 24, 2020, Telephonic Appointment Visit, Denise Hom, MD, Kaiser Permanente: Subjective Complaints: The patient reports not being back to work yet. Neck is swollen. Losing a lot of hair. Pain in the neck and numbness in the hands. Back pain where the hemangiomas are. She also complains of headaches. Assessment: Hypothyroidism due to thyroiditis. Generalized anxiety disorder. Cervical spondylosis. Plan: Ultrasound of the neck. Laboratory studies. Prescribed Levothyroxine. Follow-up with PM&R and psych.
- 29) March 25, 2020, Telephonic Appointment Visit, Carline Chen Spagnoia, MD, Kaiser Permanente: Reason for Visit: 1) Consultation: Previously sent referral 2018, but patient **DKA (diabetic ketoacidosis)**. Second request. Reportedly has Prednisone

allergy. She should be tested for Depomedrol 80 mg allergy for injection (or else requested to place on a waitlist for allergy testing, if procedures are on hold for Covid).  
2) Special testing. Assessment: Adverse drug reaction, initial encounter: Rash & itching after prednisone in 2018 but tolerated Depomedrol injections in 2019 without adverse reactions. Plan: Cleared to receive depomedrol injections - will cc chart to Dr. Chung to notify her. She is very happy to hear this & will followup with Dr. Chung for next steps in treatment.

- 30) April 20, 2020, Chronic Pain Care Management Treatment Summary - TAVs, Mobashshera Jabeen, PA, Kaiser Permanente: Treatment received from 03/25/2019 to 04/20/20. Assessment as of 04/20/20: 1) Cervical spondylosis. 2) Musculoskeletal pain. 3) Chronic neck pain > 3 months. 4) Cervical myofascial pain syndrome. Plan as of 04/20/20: The patient presents with neck and joints pain. Advised the importance of therapeutic exercise for strength and improve function. Advised to follow-up with physical therapy for stretching and strengthening. Informed patient that pharmacotherapies are only one component of pain management and stressed importance of CBTR, PT and therapeutic exercise. Recommended chronic pain management without opioids. Discussed opioid medication indication, limitations and long-term adverse effects of including tolerance, physical dependence, withdrawal, hyper analgesia, depression, mood effects, hormonal changes including hypogonadism and osteoporosis, tooth decay. Advised to avoid opioid with other Central Nervous System Depressants, such as Alcohol, Benzodiazepines, illicit drugs, or sleep aids, because of the risk of overdose and death. Discussed Pain medication advised not to take more medication than prescribed. Advised to limit Acetaminophen (Tylenol) use and not to exceed more than 3000 mg a day. Continue meloxicam (Mobic) 15 mg as needed for pain not more than 1 tablet a day with food. Avoid prolonged use as it may affect kidney. Discontinue Robaxin 500 mg and Topamax 100 mg. Continue Flexeril 5 mg and Cymbalta 100 mg. Follow up for Physical Therapy/Acupuncture. Follow up with Cognitive Behavior Therapy classes. Also follow up with Dr. Coyle, Pain Psychologist for Psycho-social evaluation at IPMP. Schedule Trigger Point Injection with me as needed for myofascial pain in neck and upper back area. Follow up Dr. Girma, Psychiatrist and Mitchell (MFT). Follow up TAV in 2 weeks or as needed to review pain medication.
- 31) April 20, 2020, Psychotherapy Treatment Summary - TAVs, Latrice Shawn Mitchel, MFT, Kaiser Permanente: The patient attended psychotherapy sessions from 02/04/20 to 04/20/20. Diagnoses: Axis I: a) Generalized anxiety disorder. b) Depressive disorder, other specified.
- 32) April 22, 2020, Office Visit, Ki-Young Yoo, MD, Kaiser Permanente: Chief Complaints: Skin lesion (face, back, arms - seen by Dr. Rodriguez on 03/09/20); hair loss. Assessment and Plan: 1) Macular amyloid/lichen amyloid: Nature of disorder discussed. Must stop rubbing, scratching; avoid friction there. Gentle care; ok to continue urea. Topical steroids not likely to be helpful here - per patient request, discussed hydroquinone-based topicals. Unclear efficacy; perhaps at least partially helpful in decreasing hyperpigmentation; she would like to try. Prescribed hq6%, kojic acid 3%,



Tretinoin 0.025%, Hydrocortisone 2.5% (ACE pharmacy). 2) Acne excoriée on face: Prescribed Hc 2.5% cream. 3) Androgenetic alopecia: Nature of disorder discussed. Try Minoxidil 2% topical first, then 5%. Followup as needed.

- 33) April 24, 2020, Intensive Outpatient Program Treatment Summary - TAVs, Jennifer Elizabeth Shortt, Lcsw/Linda Marie Silver, Lcsw, Kaiser Permanente: The patient attended Cognitive Behavioral Therapy and Supportive Therapy from 02/11/20 to 04/24/20.
- 34) May 29, 2020, Notice of Approved Loss, Alnna Essman, Disability Claim Manager (Prudential): Claim No: 12651526. Prudential has approved loss of income benefits for the patient under JP Morgan Chase Bank, N.A. Long Term Disability Plan. This disability began on March 18, 2019. This letter is the preliminary notice of lien and claim for reimbursement out of the proceeds of the workers' compensation award, if any, to the patient. We will provide a final notice of lien upon closure of our loss of income benefits claim. Please provide immediate notification of your award or denial of worker's compensation.
- 35) July 10, 2020, Progress Notes, Latrice Mitchel, MFT (Psyche Social Worker MFT), Kaiser Permanente: Subjective: The patient reports she continues to be in physical pain. She states she will get a bone scan. She states she was on the computer for some time and believes the increase in pain is a result of this. She is frustrated with her treatment and processed her concerns; "I need to take care of myself." She discussed and explored ways she can take practical steps towards taking care of herself to include being an advocate for her health and wellbeing. Assessment: DSMV: 1) Axis I: Trauma and stressor related disorder. 2) Depressive disorder, other specified. 3) Generalized anxiety disorder. Treatment Plan: Continue to practice coping skills, continue IOP (intensive outpatient program) program. Return to therapy 2 weeks TAV until further indicated.
- 36) July 28, 2020, Office Visit - Dermatology, Sharone K. Askari, MD, Kaiser Permanente: Reason for Visit: Rash, medication review. HPI: The patient here for followup rash. She was seen by Dr. Yoo - - excoriée on face and macular amyloidosis on back and bilateral upper extremities. She had bumps looked darker; thought it was whiteheads, started in November 2019. However, progress notes in past documentation had shown she had as early as 2011. Currently using urea cream 40% and, and AmLactin on arms/back with improvement. Tried Elocon, Protopic, and **Lidex ointment for face; given (doubtful print)** hydrocortisone 2.5% cream as well but doesn't feel as if it's improving. Assessment/Plan: 1) Amyloidosis, macular. Switch triamcinolone cream to: Betamethasone Dipropionate Aug (Diprolene AF) 0.05 % Topical Cream to chest, back, arms; discussed risk of skin atrophy. 2) Excoriated acne with **PN**: Discontinue picking, toners, and scrubs. Start Hydrocortisone 2.5 % Top Cream. Continue follow up with her psychiatrist to reduce anxiety and manage her medications. Followup as needed.
- 37) June 26, 2020, Deposition of Sandra Seeram Vol I: This is a 90 page deposition. The proceedings lasted for 3 hrs and 12 minutes. **Page 3-29:** Examination by David J.

Fleishman, Esq (Defense Attorney – Dietz, Gilmore & Chazen). The Deponent testified that neither of her parents nor her siblings had been diagnosed with arthritis. She had never been the victim of a violent crime, had not served in the military, and had never been a plaintiff or a defendant in a civil lawsuit. She had no other Workers' Compensation claims besides her current claims. She had not applied for State Disability prior to her claims but she did apply relating to the current case. She also received state benefits for this case for a few months of \$1,632 biweekly. She had never been in an automobile collision, had never been injured riding a bicycle or on a walk, jog, or hike, and she had never been injured participating in sports. The Deponent was currently taking Klonopin, Flexeril, Naproxen, Topamax, Levothroid, Cymbalta, and a few others she could not recall. She reported not using recreational drugs or smoking; however, she drank alcohol about two or three times a month. She also reported drinking one cup of coffee per day. She also took multivitamins and supplements including Vitamin D, Vitamin C, Vitamin A, Vitamin K, and Biotin. She testified that her insurance provider was Kaiser Permanente. All of her current medication was prescribed through Kaiser or Workers' Compensation. She was not looking for any work because of her condition preventing her. She stated she was not capable of returning to work at Chase but she was motivated because she was approaching retirement. She began working for the entity that became Chase on December 27, 1988. In the last about 32 years, she had no concurrent employment. The last date she worked for Chase before going on disability was March 15, 2019. Her annual salary was \$75,200 a year with a typical bonus of \$23,000. **Page 30-60:** Her job title was Branch Manager. Her direct supervisor was Kathy Ware who was Market Director. Her job duties included opening the branch, opening up new accounts, doing cash audits, counting items like checks or coins, scheduling for the day, managing employee calls, overriding items, hiring/firing employees, managing profit and loss statements, managing the LSAT scores, greeting people, adding money to ATM machines, and other various duties to help fix branches where she worked.

The Deponent was denied time off because of stress or her mental condition. She was written up around 1999-2000 but it was torn up. She also received some "meets minus" in 2013 in her annual reviews, which she claimed meant "needs improvement". She had never applied for unemployment benefits. She reported that her physical symptoms from the injury were currently tingling in the fingertips, tingling in the toes, numbness in the feet, pain in the knees, stiffness in the neck, headaches, and middle back pain. She lost strength in her hands more right than left, and she could not stand as long. Lifting hurt her shoulder blades. She had pain in her hands, feet, wrist, shoulder, back, head, and neck area. The Deponent rated her neck pain to be a 7/10, which was an improvement from the date of the injury. She reported that lying down, acupuncture, and Topamax helped alleviate the neck pain. She first started feeling neck pain when she was at the Hawthorne office in 2012. She sought medical attention the same year at Kaiser Permanente. She was currently still seeing Kaiser Doctors but also saw Workers' Compensation doctors for her neck. She further testified she saw acupuncture, a chiropractor, and physical therapy for her neck. She also had x-rays and MRIs. She was still experiencing numbness, pain, and tingling in her fingers, which she rated between a 5-8/10. The pain began in 2012 also and she saw a doctor in 2012. She stated that she

was not diagnosed with a finger injury but that the doctors opined the pain as a result of her neck and wrist injuries. The Deponent rated her left wrist pain a 5/10 and her right wrist pain between a 4-8/10. When she was working the pain would be in the 9-10/10 range. She received acupuncture and injections for her wrists. She also received injections for her neck provided through Kaiser. She had nothing to help alleviate her wrist pain and she indicated that wrist braces caused swelling. She added that the doctors opined the source of her toe injuries to be her neck as well. She rated the tingling, numbness, and pain in her toes as a 10/10 while she was working and currently a 5/10. The right foot was worse. She recalled that the feet and toe pain arose in about 2015. She received acupuncture for her toes and feet. She stated that her feet pain while working was an 8/10 and currently it was a 4/10.

**Page 61-90:** She further testified that she started having knee pain in the latter 2015, which she rated an 8/10 while she was working and currently now a 4/10. She received acupuncture for her knees. She could not recall what year she began having headaches. She rated the headaches a 10/10 while she was working and currently an 8-9/10. She took Mobic and Naproxen to help. She stated her back pain began about 10 years ago but no later than 20 years ago from the date of the deposition. She rated the pain a 10/10 while at work and currently a 4-7/10. She saw a chiropractor for her back and received x-rays, MRIs, and injections near her back. She testified that her shoulder pain began in 2015 and was a 9/10 when she last worked. Currently the pain was a 5-7/10. She received acupuncture for her shoulders. Her hand pain at the time of leaving work was a 10/10; however, now the right was an 8/10 and the left a 6/10. Her symptoms first began in 2012. She testified that she had diverticulitis from stress and not eating, which was advised by a personal doctor. Psychologically, Mrs. Seeram was experiencing depression, emotional outbursts, lack of patience, becoming introverted, giving up on everything, worrying, uncontrollable worrying, anxiety, becoming guarded and defensive, not trusting anyone, irritability, being embarrassed, and forgetfulness. She stated that there was increased scrutiny for employee performance and requirements also increased in summer/fall 2018, which led to her mental health issues. She sought mental health treatment prior to retaining her attorney for her Workers' Compensation Claim. The attorney referred her to the psychologist in September 2019. She saw someone for mental health through Kaiser and Workers' Compensation, but was currently being treated at Kaiser. She found that her diet helped to improve her diverticulitis and that her mental condition was improving. She suffered no additional injuries since she last worked. Her primary care physician was Dr. Denise Hom through Kaiser. She stated that her mental health condition was caused by harassment by her boss Kathy Ware during conference calls and meetings with other branch managers where Ms. Ware would yell at her, demean her, and question her actions in front of others. Ms. Ware would also make work difficult for her and make her unmotivated. The Deponent was in IOP because of the harassment at work, which was an intensive program through the mental health program at Kaiser.

38) July 24, 2020, Deposition of Sandra Seeram Vol II: This is a 29 page deposition. The proceedings lasted for 3 hrs and 12 minutes. **Page 95-110:** Examination by David J.

Fleishman, Esq (Defense Attorney – Dietz, Gilmore & Chazen). The Deponent is still seeing Dr. Denise Hom, who has been her primary care physician since 2007. She had also seen Dr. Curtis (outside of Kaiser) and Dr. Iseke at Wellness Center in Long Beach. She has an upcoming QME appointment. She had a bone scan of her entire body done at Kaiser on July 14<sup>th</sup> and she is scheduled to see Dr. Hom on 07/28/20 to discuss this. She had been diagnosed with high cholesterol and arthritis. Since being off work the Deponent noted having a lot of face care now. “I have broken out everywhere,” and has gone to multiple dermatology appointments. She also has excruciating pain that she tries to take a lot of vitamins to help with the pain and to try to care for the bones. She is trying to rest more. She does not sleep as much. Her mind “is just wandering,” adding she is not the same person. “I think the day just gets away, depressed. I don’t know how the day goes.” She has the long-term disability “trying to give me a hard time,” sending in paperwork and trying to get social security. She added that JP Morgan Chase never paid her for long-term disability, so a thousand hours of sick time was lost. She went out once to try to get something. However, she was unable to pick up what she wanted. She is unable to drive a car. She does watch TV, but “that does not work.” She would eat oatmeal for breakfast, and just heat up whatever is left over for lunch. She takes a shower once a day. A lot of fighting is going on in their house.

She describes the relationships as not the same anymore. “It’s not Covid-19, I can tell you that.” She worries a lot on her part, having a lot of anxiety. Once a week, everyone goes out, and then she will be at home. She would take medicines and vitamins morning and night. In the first volume of her deposition, the Deponent mentioned having diverticulitis and some dietary struggles. She has gained about 6 lbs, which she believes is from stress. She is unable to perform household activities. She can only make some eggs for herself. With regard to grocery shopping, she can do it if “it’s under 5 lbs.” She goes out with her family once in a while, but “it’s just too much.” She describes her face as really bad, and the sun on her face is painful. She does not feel like socializing. She does text her mother every day. She does not want anyone to see what she looks like right now. She could drive to a maximum of 15 minutes without her feet getting numb. She only walks around in the house (they live in a condo). She never smoked. If she did drink, it would probably be a half glass of wine. The last time that she took a vacation was in February. She went Florida to see her father, who was ill. Since she stopped working at JP Morgan Chase, she has not left the country. **Page 111-121:** Examination by Natalia Foley, Applicant’s Attorney: The Deponent testifies having pain and aches from her work-related stress. When driving home, she would be numb and had to call for help. There was one incident when she called Kaiser, and was told to call 911. She had to be taken via ambulance away from work. Her son came to get her from Kaiser when she got discharged.

When she stopped working, she had to go back to emergency where she was told of having anxiety. Due to stress, her skin has broken out. She has skin lacerations. She lost half of her hair. She also has stomachaches and dizziness. She was always getting sick, with constant flu and colds. She wanted to do nothing with her husband, with loss of sex drive. She had chest pain, which felt like a heart attack. She experienced stress when

sitting on a conference call, being talked down to that she could not think anymore. When sitting in a meeting and being yelled at, her stomach would hurt more. Her memory was affected. She had become very moody. "I am Miss Social," hosting all the parties and people would come to their house. She feels very isolated. She just feels like a failure right now. She had a good career and had lost everything. The Deponent is taking about 10 pills a day. They are serving medications for a "pre heart attack" and for the nerves. She describes having bone lacerations. The spacing between her neck is gone. She has bulging between the spine. She is only 51 but she feels like 70 years old. Whenever she lies down, her mind is not at rest. She would think of everything that is going on. When she finally falls asleep, she would have horrible dreams. This has been going on for the last 2 years. The Deponent has racing thoughts about work experiences - how she was treated, and about the ongoing paperwork. She is no longer the driven person that she used to be. She feels humiliated. When asked about her future, she replied, "I don't have one." She only has 3½ years to retire, now that is not going to happen.

39) August 05, 2020 (DOE), August 28, 2020 (DOR), PQME in the Specialty of Psychiatry with Psychiatric Testing, Edward Spencer, MD: DOI: CT: 05/17/2018-01/24/2020; CT: 11/16/2018-05/02/2019. Review of Records: Dr. Spencer reviewed the patient's medical/nonmedical records dated from 05/06/08 to 07/14/20. Applicant's Report of Circumstances of Industrial Stress and Strain: She was evaluated in connection with two chronic trauma claims. The first claim from November 16, 2018 through May 02, 2019 was for injuries claim to the psyche and the second from May 17, 2018 through January 24, 2020 to various parts of the body. She explains that she was employed by JP Morgan Chase Bank as a branch manager. She began working for the company Great Western Bank in 1988 when she initially worked as a teller. In 2000, she was promoted to the position of branch manager where she has remained. For the duration of her employment, the bank changed ownership twice becoming Washington Mutual and then becoming owned by Chase in 2008. In addition, she reports that from January 2002 through September 2007 and October 2015 through March 2018, she relocated to Florida and worked as a branch manager at Chase Bank in Florida. This was a transfer within the company. She states that she never had concurrent employment and always worked on a full-time basis. As a branch manager, her job duties were varied. She would be called to fill in the role of any other employee at the branch such as teller or personal banker if there was short staffing. Her other duties involved supervising the branch employees. She was responsible for making sure the bank was meeting its sales goals and productivity expectations depending on the size of the branch. The job could be more or less demanding. She was compensated by salary but also received commission payments based on her sales. With respect to the November 2018 psychiatric claim, she states that she was assigned to manage a branch in Los Angeles near the Beverly Center. After her return from Florida in March 2018, she stated that everything started out well at that branch but her supervisor, Kathy Weir, "turned on her" in the fall of 2018.

Specifically, the patient commented that during meetings of the branch managers, she would be singled out and picked on. Her performance would be scrutinized in a way that she felt was more severe than the level applied to the other managers. Ms. Weir would

call out the patient frequently, accuse her of being unprepared, and express disappointments about her performance as a branch manager. She felt that, although she **next page missing**. She states that her last day of work was March 15, 2019 after she had two emergency room visits for anxiety and physical symptoms related to stress. She felt that she had to enter the Workers' Compensation process having no other clear mechanism for advocating for herself or receiving additional treatment. She stated, "My tolerance for this has gotten worse. I get more anxious and more stressed over the years." History of Present Illness: She described a number of physical manifestations and symptoms that she was concerned about. She had pain in her neck, which she attributed to cervical disc herniation. This pain was occurring in the center of the neck and radiating to the left side. She also had upper extremity complaints, which she described as pain and weakness in her hands and wrists associated with numbness on both sides with the right being worse than the left. She had some difficulty with driving, writing, and typing. She stated that she was unable to carry weights greater than 5 pounds. She believed that this particular set of difficulties had been occurring since 2012 and had been attributed by her physicians to the herniated discs in her neck. She also reported chest pain and pressure occurring very frequently, essentially daily whenever she experienced subjective stress. She stated this that feeling occurred whenever she felt even slightly anxious. It had actually been the cause of a number of her emergency room visits, although she had not been found to have any cardiac disease. She was also concerned about anatomical prominence of the left jugulodigastric lymph node in her neck, which she had mentioned to her physicians over the years.

The lymph node had been evaluated and the prominence was anatomical although she remained worried about potential lymphatic disease or cancer. She also noted pain and derangement of the thoracic spine with "bones sticking out." She was diagnosed with hemangiomas or some kind of vascular malformation related to the spine but the details were unclear. She also noted pain in the lumbar spine associated with disc herniation. She had pain in both knees and weakness in her feet. She had numbness in her feet as well, which she stated caused her to have mobility problems. She had headaches several times a week for which she took Topamax. Without the Topamax, she stated she would have headaches every day. The headaches typically occur in the right frontotemporal area. She noted medical diagnosis of diverticulitis and dermatological diagnosis of alopecia and eczema, which she also attributed to stress. She felt self-conscious about the appearance of her skin. Psychiatrically, she noted a variety of symptoms predominantly of anxiety and depression. She described that her mood felt sad much of the time. She was pessimistic and ruminative. She stated that she has had a change in her personality over the years. She used to look forward to going to work but now, she was pessimistic about it. She was preoccupied with feelings of embarrassment and failure when she thought about work. She felt that her emotional symptoms had caused concentration problems. She felt less motivated to engage in projects around the house, less motivated to engage in activities outside the home, and more forgetful. When she felt anxious, she might experience tachycardia and palpitations. She complained of GI manifestations including frequent nausea, a feeling of abdominal fullness, and dyspepsia. She reported symptoms of **next page missing**.

Re: Patient – SEERAM, Sandra  
Report Date – August 08, 2022  
Page 54

Assessment:

Axis I: Clinical Psychiatric Syndrome and Other Conditions: Adjustment Disorder with Mixed Anxiety and Depressed Mood

Axis II: Personality and Specific Developmental Disorders: No Diagnosis on Axis II

Axis III: Physical Disorders: Multiple neurologic, orthopedic, dermatologic, internal medicine, and pain complaints, deferred to appropriate evaluating specialists.

Axis IV: Relevant Psychosocial Stressors: Occupational: Severe. Familial: Moderate. Medical: Moderate.

Axis V: Global Assessment of Functioning (GAF): GAF 55, with a corresponding WPI of 23%.

Discussion of Records Reviewed: A total of 5,785 pages of medical and administrative records were submitted and the most relevant records were summarized and discussed here. Her medical records demonstrate that she had a history of somatic symptoms related to pain in her neck and extremities that were felt to be related to stress. Interventions were documented including the prescription of Cymbalta in November 2017 by Dr. Chung, in the context of physical pain and work stress complaints. At this time, she was given medical leave to address stress. She was referred to mental health services in December 2017 and saw Sayaka Kawase, LCSW for a diagnostic evaluation, which documented severe somatic symptoms at work. The contribution of personal stressors involving living at a distance from her husband and children, which had affected their marriage. In April 2018, she saw Kevin Marsee, MD, for a psychiatric evaluation. He documented that the applicant had been a “worrier” and had a history of the development of somatic complaints related to stress. She also had emotional symptoms. He recommended integrated pain management program, which she had been referred but had not been able to participate in. Regarding her January 28, 2019 acute emotional symptoms, these were identified in the records. She was seen in the emergency department with left-sided weakness, pain, and swelling, which resolved with analgesics. The assessment was of a nonserious condition, and she was discharged to home. She followed up with Dr. Hom.

Subsequently, she attended work stress program and individual therapy during the spring of 2020. By May 2020, she was reported to be somewhat better with therapy with continued depressed and anxious mood and low energy. The therapist, Jennifer Shortt, LCSW, felt that she would be able to return to work. Her records were noted back to 2008 with complaints at the time of stress. Neurological symptoms such as paresthesias were noted on October 19, 2010 and stress again. Stress was again noted in June 2012 and Dr. Hom associated her neurological symptoms as associated with stress. Work stress was again noted on February 27, 2013. There were also primary care notes dated

September 14, 2017 describing work stress that was associated with pain in the face. An adjustment disorder was diagnosed as well. These records describe longstanding work stress, which was consistent with her account of having a job that was difficult for her, with increasing somatization symptoms and associated distress increasing particularly in 2017 and continuing to the present. **Next page missing.** Causation: She experienced an aggravation of a pre-existing condition that was caused by industrial events. Permanent and Stationary Status: Her condition reached permanent and stationary status on May 20, 2020. Future Medical Care: She should have access to continued psychiatric management and skills-focused supportive psychotherapy. Apportionment: His mental impairment arose as a result of the emotional symptoms of her stress-related condition. In Dr. Spencer's opinion, her impairment and disability were a result of the adjustment disorder. There was evidence of a clinical aggravation relative to her condition prior to the beginning of the current psyche claim, November 2018. As of December 2017, according to the records, her level of impairment was "low" and not associated with a need for off work accommodation. A GAF was not provided at that evaluation but her condition as documented appeared consistent with a GAF of approximately 65. There was a basis for a finding of a decrease in GAF by ten points to 55 as a result of the occupational stress after November 2018; apportionment of mental impairment should be along these lines. For reasons discussed regarding causation, Dr. Spencer did not find any mental impairment attributable to her physical complaints. Apportionment to prior impairment was supported by the records.

- 40) August 24, 2020, Office Visit, Christopher Michael Tran, PA-C, Kaiser Permanente: Reason for Visit: Upper back problem, neck swelling. Subjective Complaints: The patient presents to the Adult Primary Care for swelling of left side of neck within the past year. She states it is getting worse. Diagnostic Studies: 1) US neck 05/13/2020: Multiple lymph nodes are visualized in the bilateral neck. The largest measures 1.17 x .78 x .47 cm. 2) NM bone scan 07/14/2020: There is no significant pathologic tracer gadolinium. Lesion seen in the cervical, thoracic, lumbar spine or bony pelvis. There are no randomly distributed foci of increased or decreased tracer uptake throughout the skeleton. Assessment: 1) Cervical lymphadenopathy. 2) Vaccination for influenza. Plan: CT neck and check with contrast. Discussion: CT scan ordered to evaluate lymph nodes. Case discussed with Dr who agrees with treatment plan. Follow up with primary care doctor or return to the urgent care or ER if symptoms do not improve or worsens.
- 41) September 03, 2020, Encounter Messages, Denise Hom, MD, Kaiser Permanente: Dr. Hom passed a message to the patient as follows: "The CT showed mildly enlarge lymph nodes in the neck area and a few lung nodules in which the radiologist recommended we repeat the CT chest scan in 1 year. This is very common. For the neck and lymph nodes, I have referred you to the ENT (ear, nose, throat) specialist to evaluate this area."
- 42) September 11, 2020, Telephonic Appointment Visit, Denise Hom, MD, Kaiser Permanente: Reason for TAV: Telecare. Phone Visit Documentation: TAV – 08/24/20 and then office visit with other provider on 08/24/20. #) Results discussed for CT neck/chest - followup with ENT. #) The patient was not fasting for lipid and not working



on it that much. Encounter Diagnoses: 1) Abnormal gastrointestinal tract imaging. 2) Mixed hyperlipidemia. 3) Hypothyroidism due to thyroiditis. 4) Cervical spondylosis. Plan: US abdomen limited. Labs. Counseled her on low fat/cholesterol diet and exercise; recheck labs. Nurse to schedule TAV followup with this examiner by end of September, after ENT appointment.

- 43) September 23, 2020, Office Visit, Kaiser Permanente, Cristeta Lazaga Lozon, MD: Chief Complaint: Neck problem. Subjective: The patient is referred for left cervical adenopathy. She was present about 3 years ago, but noticed increase in size at the beginning of 2019. The nodes tend to flare up. She has been diagnosed with macular amyloidosis, prurigo nodularis with flare up on her forehead recently. She wants a second opinion regarding treatment. She has had night sweats for the past two years, denies weight loss. Diagnostic Studies: Reviewed CT neck and chest dated 08/25/20. Assessment/Plan: 1) Cervical lymphadenopathy. 2) Reviewed CT images with the patient. 3) Unable to palpate nodes of concern. 4) Will arrange for UTZ to see if amenable to FNA. 5) Dermatitis. 6) She requested second opinion. Referral sent to Downey.
- 44) September 25, 2020, Telephonic Appointment Visit, Denise Hom, MD, Kaiser Permanente: Reason for TAV: Telecare. Phone Visit Documentation: #) Saw ENT - utz neck with **bx** pending. #) Followup with derm in Downey. #) Has changed way of eating - will check cholesterol panel. Assessment: 1) Cervical lymphadenopathy. 2) Dermatitis. 3) Hyperlipidemia. Plan: Followup with dermatology. Utz abdomen pending. Labs were ordered; counseled patient on low fat/cholesterol diet and exercise. Nurse to schedule TAV followup with this examiner in mid 10/2020 or followup as needed.
- 45) October 07, 2020, Progress Notes - Dermatology, Pamela Gnacinski Nemzer, MD, Kaiser Permanente: HPI: Last visit 07/28/20 in Carson/South Bay Dermatology reviewed. Requested Downey Dermatology instead. The patient has seen 5 providers in South Bay within 6 years. Subjective: Here for evaluation of new bumps on her forehead with mild itch at onset for -2 months. Newest scaly lesions over eyebrows and between are itchy, which improves with home treatments and tried some of the augmented Betamethasone Dipropionate 0.05% cream from past. Reports that her upper arms and back lesions have improved a lot without bumps or itch lately. Wants to know if the current ones can be lasered off due to the appearance. She has not used Triamcinolone 0.1 % cream or Hydrocortisone 2.5% cream lately. Aware of her diagnosis of amyloidosis but not sure exactly what it is. Not aware of many lab tests done. (prior SPEP & IEP normal in 2018). ROS: Reports enlarged node on upper left neck present for many months will be biopsied tomorrow in South Bay. Assessment/Plan: 1) Papular amyloid flare - biopsy for confirmation discussed and deferred; may return if desired in future. Poorly understood nature of her skin condition was discussed, which can be associated with underlying health issues. Not likely related to her thyroid disease. Encouraged to use augmented Betamethasone Dipropionate 0.05% ointment or Triamcinolone 0.1 % cream on red itchy areas along with her home treatments. Skin atrophy or hypopigmentation

with excessive use discussed. 2) Many normal prior & recent lab tests were reviewed. Repeat SPEP & IEP per patient request.

- 46) October 16, 2020, Telephonic Appointment Visit, Denise Ge Mae Hom, MD, Kaiser Permanente: Reason for TAV: Telecare. Phone Visit Documentation: #) Neck discussed - followup with ENT. #) Lab results discussed with patient. Lost 4#; coconut milk, quinoa; doesn't like cheese; desserts. To repeat cholesterol in 2021 - will be better in 3 months per patient. #) Also discussed abdomen ultrasound results. #) Mammo - to schedule. Assessment: 1) Mixed hyperlipidemia. 2) Gallbladder polyps. Plan: Counseled patient on low fat/cholesterol diet and exercise. Followup with ENT. Nurse to schedule POEs, mammo. Followup as needed.
- 47) November 23, 2020, Videoconference Deposition of Dr. Spencer: This is a 44 page deposition. The proceedings lasted for 1 hour and 4 minutes. **Pages 5-25:** Examination by Shantey Mirzakhanyan, Esq (JP Morgan Chase; Broadspire Brea; Dietz, Gilmor & Chazen): Dr. Spencer testified that he only reviewed the patient's medical records and not any objective evidence of harassment such as HR records or personnel file performance reviews. Dr. Spencer stated that he diagnosed her with adjustment disorder with mixed anxiety and depression. Dr. Spencer found evidence of a psychiatric injury on an industrial basis for a total of 90 percent industrial and 10 percent non-industrial. The Deponent stated that the patient's psychiatric condition was aggravated by the industrial events from November 2018 to May 2019. He added that it seemed she could have had a preexisting condition that likely arose from stress-related, work-related conditions. Dr. Spencer indicated that there was documented stress in the Kaiser records as early as 2008 but the source of the stress wasn't known until about 2013. Dr. Spencer stated that another main source of stress other than work was the patient's issue with her husband where there was some kind of marital infidelity in 2004 along with a drinking problem and marital counseling. He also confirmed that she had possible stressors from moving into a new house in 2008. Dr. Spencer testified that it was not out of the realm of possibility that her hyperthyroid issue, which led to hair loss, skin conditions, weight gain, inability to lose weight, and sleep problems could have contributed to anxiety and stress, but he had not received any history about the condition from her to relate stress and anxiety as a result of his medical condition. Dr. Spencer stated that the history of high sales performance expectation from 2009 to 2012 supported the idea that the patient had experienced a lot of work-related anxiety throughout much of her career. When asked, "I mean, didn't your record review reveal that she -- her hair loss is something that stresses her out, which started after she had her second child? He replied, "Well, yes. I mean, I see that she was kind of, at the time, worried about that and sort of continued to be worried about it. And she did seem to be a very somatically anxious person. You see these patients sometimes who are constantly self-monitoring and are very alert to any changes that happen, you know. But the thing is, at the same time, we were kind of talking about that early 2008 -- early 2009 through 2012, you know, I also got the history that she was having problems at the Hawthorne branch with this other kind of manager. So, you know, the issue is trying to go back and understand what she might have been worried about 12 years ago. You know, it's possible that somatic anxieties might have

played some role in that. There was some history related to work at the time. You know, so certainly a lot that was I think going on simultaneously. And she also really seemed like a person who was very focused on her work, and, like, work was a big part of her life and her kind of sense of herself.”

**Page 26-39:** It was Dr. Spencer’s understanding that before her disability leave in March 2019, the patient had never been on any period of leave of absence due to stress. Dr. Spencer agreed that the patient was flying back and forth between California and Florida and taking care of her family members could have also caused stress in her life that was not related to work. He added that of the 90 percent industrial, some of it was pre-November 2018, but a majority of it was from the events after 2018. Dr. Spencer testified that there were stressors before and after the date. When asked, “So are you willing to prepare a supplemental report addressing an interrogatory by the defendant if I lay out all of the -- all of the factors, whether it be industrial, nonindustrial, personnel, or actual events of employment, and ask you to consider it and just prepare a report on whether or not, you know, some of those factors or a combination thereof make up industrial component of her claim versus nonindustrial? So I would actually present you with all the information that I have, with a direct citation to where I got that information, and if you can just address it in a supplemental and obviously address any other issues you feel are relevant too. He replied, “Yeah. I’m happy to do that. Also, did – if the applicant ever was deposed, I don’t think that was included.” Dr. Spencer reinstated that he would issue a supplemental report, answering concerns of other non-industrial stressors that may have arose before 2018.

48) December 04, 2020, Panel Qualified Medical Evaluation, Joanne Halbrecht, MD: DOI: 05/17/18. Review of Records: Dr. Halbrecht reviewed the patient’s medical/nonmedical records dated from 05/06/08 to 08/05/20. Chief Complaints: 1) Neck pain. 2) Back pain. 3) Bilateral hand pain. 4) Bilateral wrist pain. 5) Bilateral arm pain. 6) Bilateral knee pain. History of Present Illness: The patient reported that she began working for JPMorgan Chase on 12/27/1988. She stated that sometime in the summer of 2018, the staff was taken away, and while working as a Branch Manager, she had to do more activities. She described her activities as unlocking the branch doors and disarming the building in the morning. She did this with a partner. She also, with a partner, would get everything ready for the cash machines. She would open the vault where the door weighed 100 pounds and did this twice a day, so that safe deposit boxes could be accessed. The cash vault door weighed 50 pounds. She would fill the cash machine up 4-5 days a week, which included placing bricks of \$20s that have \$40,000-\$80,000 in the bricks, and sometimes she would load \$160,000. Another person would observe while she put the cash in the machine. She did this once a day four times a week. They had three machines with \$5s, \$20s, and \$100s. She gave her tellers coins and cash and they had multiple boxes of coins weighing between 25-40 pounds, and she did this 4-5 times a day. She would cover the tellers over their lunches and open up new accounts for clients. She would climb to change merchandise promotions that were mounted on the walls and did this sometimes weekly, monthly, or quarterly. She would climb a ladder to lift safe deposit boxes for clients and sometimes have to reach overhead. She stated that she was

on the computer all the time, but also stated that she did all of these other activities all the time. She initially stated that she was on the computer 8-10 hours a day and then changed the time period to 7 hours a day.

She reported that she started feeling pain in the 2012 in the aforementioned body parts and went to her PCP and was referred to physical therapy and was told that she had degeneration in her neck. Her symptoms became worse in 2015. An ergonomic evaluation was performed of her workstation and she reported that nothing was changed with it. This evaluation was done before she arrived at her managerial position in 2018. The desk had a pullout for a keyboard, and she stated that this was comfortable to use, but the tele lines were not. She stated that the doctors recommended modified duty, but that was not being followed. She received her treatment through workers' compensation, and she reported that the claim was denied, so she got treatment through Kaiser. She stated that she had a separate CT claim for psych, which had been denied. She reported that she sought the advice of an attorney for all of the years that she worked and "all (her) body parts are broken," stating that it "was not fair" that some branches have help and others don't. She said repeatedly that this was "not fair." She stated that she had an episode in January 2019 when she was driving to work. She felt due to cumulative trauma sustained while working as a Branch Manager for JPMorgan Chase. PE: General: There was tenderness everywhere that was palpated over her entire body, some areas more than others. She had jerky motions with attempt at range of motion of body parts. Cervical spine: Noted decreased and painful ROM. She reported decreased sensation on the volar and dorsal aspects of all digits to light touch and pinprick. Bilateral shoulders: Noted positive Hawkins Impingement testing, she reported pain that extended down the entire right upper extremity. With Hawkins Impingement testing and Resisted Cross-Arm testing of the left shoulder, she reported pain that extended down the arm. Hands: She stated that her fingers looked like a skeleton. There was a negative Phalen's, Tinel, and Carpal Compression bilaterally, which did not make her claimed numbness worse. She reported decreased sensation to light touch of bilateral lower extremities in a stocking distribution to light touch and intact to pinprick.

Diagnoses: 1) Nonspecific neck, bilateral shoulder, lumbar, and bilateral lower extremity pain. 2) Nonanatomic decreased sensation of bilateral hands and bilateral lower extremities. Discussion: The patient is claiming cumulative trauma to her neck, back, arms, hands, wrists, and knees due to cumulative trauma sustained while working as a Branch Manager for JPMorgan Chase. Her job duties and medical history were noted as indicated above in HPI/PMH sections. Medical records document evaluation by Dr. Hom on 09/29/2010. She had a one-year history of right thumb pain that was intermittent and worse with typing and writing a lot. On exam, there was a positive Tinel's and Finkelstein's with a negative Phalen's bilaterally. She was diagnosed with wrist tendinitis on the right with possible de Quervain's and carpal tunnel syndrome. She was referred to PM&R for further evaluation. PM&R evaluation was performed by Dr. Acord on 10/19/2010. **History significant for bilateral hands and right forearm aching and tingling for several years. Her complicating factors was that she uses her hands all day at the bank.** On exam, there was decreased range of motion of the cervical spine

with spasm of the upper trapezius bilaterally. There was right upper extremity hypesthesia. Positive Tinel's and Compression test of bilateral wrists. Nerve Conduction studies were recommended and cervical x-rays as well as PT. X-ray of the cervical spine on 10/19/2010 was significant for C5-C6 degenerative disc disease with decreased disc height. In her PT evaluation on 11/03/2010, she had throbbing pain in bilateral upper trapezius and her upper back between the scapula with numbness and tingling of bilateral hands. **She had been provided with wrist braces. History indicated that she was a bank manager and not in any one position for extended periods. She was unable to look over her right shoulder when driving without turning her body and was unable to stand and prepare dinner more than 2 hours. The onset of her pain was in January of 2010 and was worse for two months possibly due to having worked 10-hour days.**

She received several PT treatments. On 04/05/2011, Dr. Hom reported that she had right-sided facial numbness with a rash on her left side of her face for four months and she had thickened scaling plaques on both upper lids and her left cheek. Dermatology evaluation was performed by Dr. Karukonda on 04/20/2011. She had lichenified plaques on her face and she was prescribed triamcinolone. On 09/30/2011, Dr. Mohageg reported that she had a history of cervical disc disease and had been doing PT and was having pains in her upper back and both shoulders for two weeks. The previous week she had pressure in her chest and she felt like the right side of her chest was swollen. On exam, there was tenderness of the paracervical muscles and trapezius bilaterally. **On 06/08/2012, Dr. Hom reported that she had a history of right thumb/wrist pain for years with chronic neck problems that were worse with typing and writing** a lot and improved with thyroid treatment and exercises. She had right-sided facial numbness for a few months that was intermittent and occurred with stress and when her neck was painful. On exam, there was **a positive Finkelstein and Tinel on the right.** She had a vitamin D deficiency. She was diagnosed with **right carpal tunnel syndrome.** On 10/12/2012, Dr. Pickering reported that she had tingling in her right arm for weeks only in the morning and it goes away within 5 minutes. She had ongoing neck pain, but it was not as bad as previous. She works as a branch manager and was only on the computer for 15 minutes at a time and had no symptoms. The left hip bothers her at times as well. On exam, the cervical spine had mild tenderness. Sensation was normal in bilateral hands. She had little pain in the right forearm with manipulating the right wrist. On 11/02/2012, Dr. Nguyen reported that she had nocturnal hand numbness and tingling bilaterally. On exam, there was cervical spine tenderness. Diagnosis included carpal tunnel syndrome, though there was no exam of the wrists or Phalen's testing.

A cock-up wrist splint was recommended as well as avoiding repetitive gripping and grasping. Annual exam was performed by Dr. Rabanipour on 02/27/2013. Musculoskeletal exam was without abnormality. On 06/05/2014, Dr. Hom reported that she would like to be referred to podiatry because she had calluses on her toes. She continued to report numbness and tingling on the skin of the right side of the face possibly due to stress. Neurologic exam was normal. Dermatologic exam was performed by Dr. Boland on 06/12/2014 and she was diagnosed with pilaris and eczema. On

Re: Patient – SEERAM, Sandra  
Report Date – August 08, 2022  
Page 61

06/14/2015, podiatric evaluation was performed by Dr. Bragg. History significant for bilateral fourth and fifth digits pain for six months. It mainly occurred in close toed shoes. She was diagnosed with acquired bilateral hammertoes. On 09/04/2015, Dr. Hom reported that she had neck, back, shoulder, and right thumb pain. On examination of the neck, there was decreased range of motion with tenderness over the trapezius. Examination of the right wrist had a positive Tinel and Phalen's and bilateral shoulders had full range of motion and negative provocative testing. Her diagnoses included cervical spondylosis, paresthesia of the upper limb, and right carpal tunnel syndrome. Labs were ordered. She was referred to PM&R. On 09/18/15, Dr. Chung reported that she had pain in her neck and bilateral hand numbness, right worse than left. On exam, there was decreased range of motion of the cervical spine and tenderness. There was a positive Phalen's and plus or minus Tinel of the left elbow. Her diagnosis included chronic neck pain and MRI was ordered of the cervical spine. Cervical spine MRI on 09/30/2015 was significant for broad-based disc osteophyte with mild central canal stenosis at C5-C6 and degenerative disc disease. **EMG/NCV on 12/17/2015 was significant for mild bilateral carpal tunnel syndrome.** On 06/23/2016, Dr. Hom reported that on exam there was decreased range of motion of the cervical spine and tenderness over the trapezius.

On 06/24/2016, Dr. Hom reported that she was concerned about her husband's drinking and she had unresolved concerns about a history of cheating/trust in the past when their son was 1-year-old. She was advised to follow up with psych. On 03/17/2017, Dr. Hom reported that she had left hip and left lower quadrant pain for months with chronic neck, back, and shoulder pain. On exam, there was decreased range of motion of the neck with tenderness of the bilateral trapezius. On 09/05/2017, **Dr. Kawasaki reported that she had bilateral hand pain with numbness at night for more than one month as well as neck pain, which was getting worse.** She reported burning on the top of her hand at the second digit. On exam, there was decreased sensation of the right hand of the dorsal second digit and thumb. She was diagnosed with chronic neck pain in likely a C6 distribution. He recommended referral to PM&R. On 09/21/2017, Dr. Dao reported that Elavil made her hand numbness worse. On 11/29/2017, Dr. Chung reported that she had pain in her neck with numbness and tingling in her arms. On exam, there was tenderness of the cervical paraspinals and upper trapezius with a head forward position and rounded shoulders. She was diagnosed with cervical myofascial pain syndrome, disc degeneration, and chronic neck pain. She was referred to PT. On 12/13/2017, Dr. Bishay reported that she had neck pain radiating to her head, arms, and hands with tingling in her right hand on and off only at night. She was diagnosed with carpal tunnel syndrome. On 12/14/2017, PA Woysner reported that stress increases her neck pain and headaches. She reported that her neck pain was constant even when she was off work for two weeks, she had no improvement, and it was aggravated by sitting for a long period of time, lifting, standing, and climbing. She had tried nortriptyline, but it made her feel too groggy and they switched to duloxetine. She uses meloxicam sparingly. She recommended seeking mental health professional for anxiety/depression which has improved since she started Cymbalta. On exam, there was a few beats of unsustained clonus of bilateral

Re: Patient – SEERAM, Sandra  
Report Date – August 08, 2022  
Page 62

lower extremities and hypertonicity in paraspinal muscles and right shoulder. She recommended referral to PT.

Psych evaluation was performed by Dr. Coyle on 12/14/2017. History significant for chronic neck pain and emotional work-related stress aggravated her pain. She was scheduled for an intake with psych next week. On 02/16/2018, Dr. Chung reported that she had improved neck pain and requested a refill on meloxicam. On exam, there was mild tenderness of her cervical paraspinals and upper trapezius with spasms. On 02/22/2018, Dr. Hom reported that she had **chronic neck pain with numbness and tingling in bilateral hands**. On 03/23/2018, Dr. Hom reported that she had pain in the neck and upper back with stress and tingling in both of her feet and it felt like her left lower extremity was twitching and moving. On exam, there was decreased range of motion of the cervical spine and tenderness of bilateral trapezius. She was diagnosed with cervical myofascial pain syndrome and spondylosis with numbness and tingling of the skin of bilateral feet and right carpal tunnel syndrome. She recommended PM&R referral. She was evaluated by Dr. Chung on 03/16/2018 for neck pain that was radiating to her arms. TPI was offered, but was declined. On 04/05/2018, Dr. Hom reported that she had decreased range of motion of the cervical spine with tenderness of bilateral trapezius. On 04/10/2018, Dr. Chung reported that she had chronic neck and upper back pain with numbness and tingling of bilateral lower extremities and occasional low back pain. **Her neck pain was worse with keyboard use**, work, travel, flying, and stress. Her back pain was worse with standing. On exam, there was a sensory deficit of bilateral toes and tenderness of the cervical spine. She declined orthopedic referral. She was referred to OT. Psychiatry evaluation was performed by Dr. Marsee on 04/11/2018 and the diagnoses were indicated as follows: 1) Generalized anxiety disorder, rule out somatic symptom disorder. Long history of somatic/physical symptoms followed by physical medicine for a few years, seen once by neurology and determined to have unspecified paresthesias. Has always been a worrier about finances and the future, and a history of muscle tension and other somatic complaints when she is under stress. She has insomnia, irritability, restless, and anxiety when stressed.

Somatic symptoms are the most distressing for her and might have limited her ability to work recently. She recently made the connection between stress, anxiety, and her physical discomfort. Her somatic symptoms are her primary focus and have been most disabling regarding her work function. She has had very dedicated care by physical medicine, and she felt that she would really benefit from psychotherapy, but had not been able to commit in large part due to denial of her disability claim last year. MRI on 04/24/2018 of the lumbar and cervical spine are significant for mild degenerative changes at C5-C7 with mild narrowing of the central spinal canal and mild degenerative changes of the lumbar spine. EMG/NCV on 04/27/2018 of bilateral lower extremities was without abnormality. On 10/03/2018, Dr. Chung reported continued neck pain radiating to the arms with numbness and tingling. On exam, there was tenderness over the cervical paraspinals and upper trapezius. On 01/28/2019, ED evaluation was performed by Dr. Negus. History significant for left arm pain with weakness since that morning with pulling sensation in the back of her neck to her left arm and hand. The numbness and

weakness had resolved. She was diagnosed with neck pain. On 01/30/2019, Dr. Hom reported that she had pain in her neck and upper back as well as hand edema since 01/08/2018. On exam, there was decreased range of motion of the cervical spine with tenderness of bilateral trapezius. On 02/14/2019, Dr. Chung stated that she wanted FMLA for time off for treatment. She recommended neuro referral for paresthesias and ortho referral for bilateral carpal tunnel. On 02/22/2019, PA Jabeen reported that she had neck and joint pain since 2002 due to work-related stress/increased workload and pain radiated to both bilateral upper and lower extremities with numbness, tingling, and weakness. She stated that she felt her current supervisors were not fair with her increasing her workload and with unreasonable expectations to make her push herself to limits and she felt that she was stressed. She felt that her supervisor was not allowing her to go to PT and acupuncture or regular doctor visits, but now she had decided to take care of herself working with Dr. Chung to get off work.

Pain diagram circles an area at the top of the head, left chest, cervical, lumbar spine, anteroposterior knees, and bilateral feet as the source of pain. MSK exam is reported as “tenderness.” On 02/27/2019, Dr. Truong reported that she had bilateral carpal tunnel syndrome and recommended a trial of carpal tunnel corticosteroid injection, which the patient deferred. He recommended following up with PM&R and primary care as needed. Thoracic spine MRI on 03/06/2019 was without abnormality. On 03/14/2019, Dr. Hom in her annual visit reported that PE of the cervical spine was significant for decreased range of motion with tenderness of bilateral trapezius. He stated that her symptoms were likely multifactorial and may be stress related. Prior EMG with mild bilateral carpal tunnel syndrome. On 04/11/2019, Dr. Chung reported that she had ongoing neck pain and swelling in the left supraclavicular area and pain that was triggered by stress at work and a hostile work environment. She was diagnosed with chronic pain syndrome. On 05/14/2019, Dr. Hom reported that her neck pain was better when she was not working. Initial chiropractic evaluation was performed by Harold Iseke on 07/10/2019. History significant for CT 05/17/2018-05/18/2019 with headaches, neck, bilateral wrists, hand, anxiety, stress, and depression. He diagnosed cervical radiculopathy with disc displacement, cervicalgia, thoracic spine pain, right wrist pain, right upper extremity mononeuropathy, left wrist sprain with pain in bilateral hands and fingers, left hand pain and chronic myositis. He recommended EMG of bilateral upper extremities and chiropractic treatment and acupuncture. On 07/22/2019, PA Jabeen reported that her pain was better with her current medication and she felt less stressed since filing a workers’ compensation case. **On 07/29/2019, Dr. Chung reported that she had pain in her low back, and they were giving her tasks that she should not be doing as a bank manager such as handling money, stamping all day, and tele-banking aggravating her neck and back pain.**

She reported stress and anxiety related to work. Her exam was without abnormality. She recommended referral to psychiatry. On 08/19/2019, PA Jabeen reported that she had worse neck pain since her work health insurance wanted her to go back to work. On 08/26/2019, Dr. Jabeen performed a trigger point injection in the trapezius. Psychology evaluation was performed by Dr. Windman on 10/07/2019. Diagnoses included major



depressive disorder and psychological factors affecting other medical conditions. She underwent CBT sessions. On 10/10/2019, PA Jabeen reported that her trigger point injection was still helping with her pain. On 11/12/2019, PA Jabeen reported that her neck pain had become worse and her trigger point injection wore off. He wanted to try another injection. On 01/08/2020, Dr. Iseke declared her MMI and released her from care. On 01/10/2020, Dr. Curtiss issued a PR-4 Report. In that report, it states that she experienced bank robberies while at JP Morgan in 1989, 1993, 2000, and 2007 and no claims were filed, and as a result of the robberies, she continued to feel safe at the bank. She filed a stress case in 2012 when she also injured her neck, back, and knees due to heavy lifting. She had not yet recovered from those injuries. She demonstrated diminished cognitive function in the clinical interview where she was rambling, defective in recall, and revealing of defects and concentration. It appeared that most likely her cognitive deficits were caused by emotional reactive confusion. Her psychological results were massively abnormal indicating severe depression, severe anxiety, severe hopelessness with marked concern for health problems, marked paranoid thinking, marked social difficulties, and diagnosis included psychological factors affecting medical conditions. From her history and exam, she had been temporary totally disabled on an emotional basis from her last day of work at JPMorgan Chase Bank on about 03/15/2019 to the present.

She was assigned a 30% WPI, 100% industrial and 60% due to disturbing events at work and 40% to the underlying impairment caused by pain and disability. On 01/30/2020, Dr. Curtiss recommended more CBT sessions. On 02/20/2020, PA Jabeen reported that she was feeling better, but had a rough time when she was asked to return to work. It was very hard for her and she had to go through therapy. She continued to have neck pain. This was a telephone appointment. On 03/19/2020, dermatologist, Dr. Rodriguez, diagnosed lichen simplex chronicus stating that it was hard to know if it started with a true dermatitis or possibly pilaris. On 03/23/2020, Dr. Chung reported that she had chronic neck pain radiating to her shoulders. She had intermittent numbness in bilateral hands. Her work comp claim was denied. She generally felt much better since she was off work and seeing psych for anxiety/depression/stress. On 04/08/2020, PA Jabeen reported in a phone visit that she still had neck pain and she recommended trigger point injection and continued medical management. On 04/20/2020, PA Jabeen reported on a phone visit that her neck pain and headaches had gotten worse in three weeks. Dermatologic evaluation was performed by Dr. Yoo on 04/22/2020. History significant for onset earlier this year; however, the doctor stated that progress notes indicate that it was present as early as 2011. In her deposition on 06/26/2020, she stated that since she was off work she has broken out everywhere and has had multiple dermatology appointments. She has excruciating pain. Her mind wanders and she is not the same person. She is applying for disability through Social Security. JPMorgan Chase never paid her long-term disability, so thousands of hours of sick time was loss. There is a lot of fighting going on in her house and her relationships are not the same. She has a lot of anxiety.

She is unable to perform household activities and can only lift if it is under 5 pounds. She does not feel like socializing. She will drive a maximum of 15 minutes without her feet getting numb. She only walks around her condo. She has pain and aches from work-related stress. She stated that due to stress her skin is broken out. She has lost half of her hair. When sitting at a meeting and being yelled at, her stomach would hurt more. Her memory was affected. In the past, she was very social. Now, she feels like a failure. She describes having bone lacerations and the space between her neck was gone and she has bulging in her spine. She felt like she was 70. Psychiatric PQME performed by Dr. Spencer on 08/05/2020 reported CT between 11/16/2018-05/02/2019 and 05/17/2018-01/24/2020. He assigned a 20% WPI with TTD 03/15/2019-05/20/2020 and apportioned 70% to occupational stressors, 20% to stressors related to bank robbery, and 10% non-occupational due to frequent moving and marital conflict. On physical examination, there was tenderness everywhere that was palpated over her entire body, some areas more than others. She had jerky motions with attempt at range of motion of body parts. She reported pain with range of motion of the cervical spine. Cervical flexion 30 degrees, extension 5 degrees, left and right rotation 40 degrees, and left and right lateral bending 20 degrees. She reported decreased sensation on the volar and dorsal aspects of all digits to light touch and pinprick. Bilateral shoulders had full range of motion and with Hawkins Impingement testing, she reported pain that extended down the entire right upper extremity. With Hawkins Impingement testing and Resisted Cross-Arm testing of the left shoulder, she reported pain that extended down the arm. When examining her hands, she stated that her fingers looked like a skeleton. The appearance of her fingers were normal. There was a negative Phalen's, Tinel, and Carpal Compression bilaterally, which did not make her claimed numbness worse. There was 5/5 strength with resisted muscle testing of bilateral upper extremities. The lumbar spine had full range of motion without muscle guarding.

She reported decreased sensation to light touch of bilateral lower extremities in a stocking distribution to light touch and intact to pinprick. Negative straight leg raise bilaterally. 5/5 strength with resisted muscle testing of bilateral lower extremities and full range of motion of the hips, knees, and ankles. Cover letter provided from Shantey Mirzakhanyan states that on 05/22/2019 she filed a claim for CT from 05/17/2018-05/18/2019 for an injury to her neck, upper extremities, back, muscles, spine, shoulders, scapula, clavicle, and lower extremities, and later amended cumulative trauma to end 01/22/2020. She claims injury to the neck, wrist, fingers, spine, legs, feet, and knees, upper and lower back due to stress and strain from repetitive movement over a period of time. Defendant denied liability for this claim based on the lack of medical factual and legal evidence to substantiate a work-related injury. Her PTP was chiropractor, Harold Iseke, who treated her from 07/10/2019- 01/08/2020 and found her P&S; however, defendant objects in part to the findings of Dr. Iseke since he did not review her extensive medical record for services rendered between 2008-2020. Defendant requests that Dr. Halbrecht review all medical records and provide opinions. She filed a separate CT from 11/16/2018-05/02/2019 for psychiatric injury, which was also denied. She was evaluated by PQME on 08/28/2020 who found her P&S for her psychiatric claim of 05/20/2020. The remainder of the letter asks that Dr. Halbrecht include the components of a standard

QME report. MMI Status: Cervical spine, bilateral wrists, and hands were Permanent and Stationary and at MMI as of 12/04/2020. Impairment Rating: Cervical spine: 5% WPI. Bilateral wrists/hands: 4% WPI. Total WPI: 9%. Causation: Medical records substantiated a causal relationship to her bilateral wrist and hand pain and cervical spine pain and cumulative trauma sustained as a result of work activities between 09/29/2009-01/22/2020. The physical examination was consistent with her described mechanism of injury.

On 09/29/2010, Dr. Hom reported that she had a one-year history of right thumb pain that was intermittent and worse with typing and writing. She had a positive Tinel's and Finkelstein's. On 10/19/2010, Dr. Acord reported that she had a history significant for bilateral hands and right forearm aching and tingling, which was complicated by the fact that she used her hands all day at the bank. The bold areas of Dr. Halbrecht's discussion were describing each of the medical reports of her ongoing neck and bilateral upper extremity pain that was aggravated by work-related activities. Medical records did not substantiate a causal relationship to finger pain and cumulative trauma sustained between 05/17/2018-01/22/2020. There was no documentation in the medical record of pain in her fingers and the source of her pain or complaint that her fingers were like "skeletons" and may have been due to conversion disorder. Medical records did not substantiate a causal relationship to her bilateral legs, bilateral feet, bilateral knees, and low back pain and cumulative trauma sustained between 05/17/2018-01/22/2020. The first documentation in the medical record of low back pain was on 04/10/2018 by Dr. Chung when she also reported numbness and tingling in bilateral lower extremities. Again, on 07/29/2019, Dr. Chung reported that she had low back pain and described activities such as handling money and tele-banking that aggravated her neck and back pain; however, the described mechanism of injury would not result in low back pain, bilateral leg or foot pain. The cause of her pain was indeterminate as she was tender everywhere that was palpated and described numbness in a stocking distribution of bilateral lower extremities. In addition, she had full range of motion of the lumbar spine, knees, feet and ankles with 5/5 strength with resisted muscle testing. Given her psychological history, Dr. Halbrecht suspected conversion disorder to be the source of her pain.

Apportionment: Cervical spine x-ray was significant for degenerative disc disease and spondylosis, which significantly contributed to her impairment and, thus, Dr. Halbrecht apportioned 60% to pre-existing degenerative changes and spondylosis and 40% to cumulative trauma sustained between 09/29/2009-01/22/2020. Bilateral wrists and hands: There was an association of development of carpal tunnel syndrome with low Vitamin D as well as diffuse joint pain and muscle weakness. Medical records document that she had a history of Vitamin D deficiency and, thus, Dr. Halbrecht apportioned 20% of her bilateral wrist and hand impairment to pre-existing Vitamin D deficiency and 70% as the result of cumulative trauma sustained between 09/29/2009 through 01/22/2020. Periods of Disability: Typically Dr. Halbrecht deferred to the medical records for periods of temporary and partial disability, which were determined by the treating physician; however, there was no documentation of that in the medical record for her musculoskeletal complaints, thus, Dr. Halbrecht would conclude from her physical

examination that at that time, she would have required work modifications or being off work so as not to aggravate her symptoms. She was Temporarily Partially Disabled from 09/29/2010 to 12/03/2020. Work Restrictions: Recommended no repetitive twisting or turning of the cervical spine. No repetitive gripping or grasping or awkward movements of bilateral wrists and hands. No lifting more than 5 pounds to the waist or overhead. Future Medical Care: Recommended physical therapy for the cervical spine twice a week for six weeks to emphasize postural training and a home exercise program. NSAIDs, neurolytic, and muscle relaxants at a therapeutic dose. Bilateral wrists and hands: Cock-up wrist splints. Physical therapy twice a week for six weeks to include modalities. NSAIDs at a therapeutic dose. If neurologic symptoms were more consistent, repeated EMG/NCV and referral to orthopedic surgeon fellowship trained in hand.

- 49) December 08, 2020, Integrated Pain Management Program - TAV, Virginia A. Coyle, Psy.D., Kaiser Permanente: Identifying Information: The patient was referred to this psychologist to determine dispositional readiness for participation in IPMP. Currently, not working due to pain. Stopped working last month. Currently living with and children. Plan/Recommendations: Attend virtual CBTR classes - January. She was added to interest list. Follow-up with IPMP psychologist: 01/11/21.
- 50) January 05, 2021, Integrated Pain Management Program – Physical Management Session Note, Alice Langit-Cole, RPT, LAc, Kaiser Permanente: Patient Attended Physical Management Education Session week# 1. Diagnosis: Chronic neck pain.
- 51) January 13, 2021, Progress Notes, Denise Ge Mae Hom, MD, Kaiser Permanente: Phone Visit Documentation: #) Mammogram question - wants ultrasound; with identical diagnosis and now precancerous cells - had to remove duct. Tissue was dense and had calcium deposits. **Pgm** with breast CA. #) Face was scaly due to Topamax - someone else with same **prescriptions**; full dose with same thing, dermatology said was picking at it. #) Neck pain - acupuncture closed now during Covid-19 pandemic - followup with pain management and PMR. #) Covid-19 vaccine questions. Assessment: 1) Family history of breast cancer. 2) Cervical spondylosis. 3) Coronavirus Covid-19 vaccine counselling. Plan: Referral general surgery. Referred to breast clinic for further evaluation of mammogram results. She had family history of breast cancer. Followup with pain management and PMR for neck. Covid-19 vaccine information discussed. Followup as needed.
- 52) January 19, 2021, Progress Notes, Kelly Williams, MSN, NP-BC, Kaiser Permanente: Reason for Visit: Consultation, breast care. Assessment: 1) Fibrocystic change of bilateral breasts. 2) Mammographic bilateral breast microcalcification. Plan: No significant physical findings. Reviewed recent benign mammogram findings with patient. Reassured. Discussed calcifications are often benign and have characteristic appearance on mammogram but if there had been any atypical features she would have been recalled for diagnostic imaging. Discussed that mammography is the gold standard for breast cancer screening. Ultrasound is best used for focal findings such as palpable

masses or abnormal mammogram findings. Discussed high false-positive rate with screening ultrasound. Discussed that screening ultrasound is not standard of care. Breast self-exam reviewed and encouraged. Routine screening mammogram schedule. Latest American Cancer Society guidelines for average risk women (no known genetic mutation in family): Optional mammogram yearly age 40-44, yearly age 45-55, every 1-2 years age 56 and up, and as long as you are healthy. Follow up as needed for any new breast lump that persists. She indicates understanding of these issues and agrees with the plan.

53) February 16, 2021, Integrated Pain Management Program – Physical Management Session Note, Alice Langit-Cole, RPT, LAc, Kaiser Permanente: Patient Attended Physical Management Education Session week# 7. Diagnosis: Chronic neck pain.

54) February 16, 2021, Integrated Pain Management Program - Virtual CBTR Group Note, Virginia A. Coyle, PsyD, Kaiser Permanente: The patient attended pain management group series session #7/8.

55) March 11, 2021, PQME’s Supplemental Report, Edward L. Spencer, MD: DOI: CT: 05/17/18-01/24/20; CT: 11/16/18-05/02/19. Review of Records: Dr. Spencer reviewed the patient’s medical/nonmedical records dated from 08/14/09 to 01/13/21. Conclusions: This examiner had attempted to identify on detailed re-review of the previous medical records and nerve information submitted. The specific point at which the patient developed a psychiatric disorder. The causes of that disorder, the nature of her impairment at that time, the circumstances of her clinical worsening, her final level of impairment, and the stressors and injurious factors giving rise to that final impairment. It does appear that the onset of her injury was prior to the claimed CT period with there being worsening during the CT period and after owing to the contribution of a mixture of old and new industrial and nonindustrial factors, and that worsening led to an increase in her impairment and the final impairment rating.

| Cause of Disability   | Interpretation  | Percentage | Reason   |
|---|---|------------|--|
| Persistent chronic health anxiety   | Nonindustrial   | 5%         | Continued preoccupation documented in medical records  |
| Emotional reaction to persistent orthopedic pain/neck pain                    | Industrial relatedness deferred to orthopedic opinion | 15%        | Continued complaints of pain in neck, hands, various body parts separate from somatic preoccupation, though these complaints appeared relatively |
| Family financial stressors due to lack of work by applicant in September 2019 | Nonindustrial   | 5%         | Documentation of Dr. Girma indicating this stressor, though limited effect given applicant’s receipt of private disability                       |

|  |  |     |   |
|--|--|-----|---|
|  |  |     | insurance benefits and adequacy of husband's work income to support family expenses as described in social history as described in social of this examiner's initial report |
| Anxiety, decreased confidence, and pessimistic expectations related to perceived harassment by Ms. Ware and sales pressure beginning in the fall of 2018 | Industrial (deferred to Trier-of-Fact on whether this anxiety results from an actual event of employment vs a perceived event) | 60% | Clear temporal relation between the onset of this complaint and significant worsening of symptoms leading to ER visits and inability to continue working.                   |
| Emergence of previously subclinical personality trait dysfunction  | Nonindustrial  | 10% | Emerged in spring 2020 intensive outpatient treatment, no evidence of this specific impairing factors in records prior  |
| History of exposure to bank robberies from 1995-2009   | Industrial   | 5%  | Increased apprehensiveness about returning to work, reactivity to bank environment. Limited contribution because of remoteness of stressor and lack of evidence of PTSD.    |

The decrease in GAF from 65 to 55 corresponds to a change in level of WPI from 8 to 23. Therefore, in this examiner's opinion, the increase in WPI from 8 to 23 accounted for by the stressors and factors listed above, which all should be subject to the findings of the Trier of Fact as to their industrial relatedness.

56) May 21, 2021, Complete Psychiatric Evaluation, Gull Ibrahim, MD: HPI: The patient states, "I can't work because I have degenerative disc disease in my neck. Few discs are also herniated. I have arthritis. I have numbness in my both feet. When I walked here, it is swollen. I have also numbness in my hands, carpal tunnel syndrome in both hands. Confused and forgetfulness, I am nervous and jumpy. I am not getting along with employees. In 2002, I was working in Stopped working in March of 2019. I have anxiety from everything. I am stressed out. I have stomach problem from stress. I have forgetfulness problem since 2017. It is continuously there. My anxiety is there since 2009, it is continuously there. I am scared of loud sound, yelling and door slamming. I deal with my anxiety by staying home. I am on Cymbalta, the psychiatrist gave it to me

Re: Patient – SEERAM, Sandra  
Report Date – August 08, 2022  
Page 70

for pain, anxiety, and depression since 2017. Also, I have been going for counseling. Now, it is because of the Covid, it is on the phone, virtual, every two weeks. These medications and counseling helped little bit. They calm me down. ADLs: ADLs were reviewed.

#### Diagnoses by DSM IV

Axis I: Mood Disorder due to General Medical Condition  
Anxiety Disorder, Not otherwise Specified

Axis II: Deferred

Axis III: As per medical history

Axis IV: Chronic medical illness

Axis V: Current GAF: 55

Functional Assessment: Based on the patient's history and mental status examination and from the psychiatric point of view alone while on medications, she has the following functional limitations. His ability to relate to and interact with public, co-workers, and supervisors is normal. Her ability to understand and carry out simple instructions is normal. Her ability to maintain concentration, attention and persistence required to do work related activities is mildly limited. Her ability to understand, remember and carry out complex or detailed instructions is mildly limited. Her ability to cope with workplace stress is mildly limited. Prognosis: From a psychiatric standpoint, her prognosis is guarded. Financial Capabilities: Based on this presentation, she is capable to handle her personal funds at this time.

57) December 17, 2021, Primary Treating Physician's Initial Evaluation Report, Marvin Pietruszka, MD/Koruon Daldalyan, MD: DOI: CT: 05/17/2018-05/18/2019; CT 11/16/18-05/02/2019. Job Description/HPI: Remained unchanged. Current Status: The patient now complains of continued skin irritation, headaches, acid reflux, anxiety and depression and she has gained approximately 15 pounds weight. She also complains of musculoskeletal pain throughout her entire body. Review of Systems: The patient complains of headaches, dizziness, lightheadedness, visual difficulty, cough, throat pain, jaw pain, jaw clenching, dry mouth, chest pain, palpitations, and shortness of breath. She denies a complaint of ear pain, hearing problems, sinus problems, sinus congestion, postnasal drip, wheezing, hemoptysis or expectoration. She complains of abdominal pain, burning symptoms, reflux symptoms, nausea, diarrhea alternating with constipation, and 15 pound weight gain. She complains of urinary frequency and urgency. She complains of symptoms of sexual dysfunction. Her musculoskeletal complaints involve cervical spine pain 9/10, thoracic spine pain 9/10, lumbar spine pain 5/10, bilateral shoulder pain 8/10, bilateral elbow pain 6/10, bilateral wrist pain 8/10, bilateral hand pain and numbness 8/10, bilateral hip pain 7/10, bilateral knee pain 8/10, bilateral ankle pain

8/10, bilateral foot pain and numbness 9/10. There is a complaint of peripheral edema and swelling of the ankles. Her psychosocial complaints include anxiety, depression, difficulty concentrating, difficulty sleeping, difficulty making decisions and forgetfulness. There is a complaint of hair loss from the scalp. There are dermatologic complaints. There is intolerance to excessive heat and cold. There is a complaint of diaphoresis, chills or lymphadenopathy. PE: BP: 100/60. Wt: 142 lbs.

Radiological Data: 1) An x-ray of the chest (two views) is taken today and is normal. 2) An x-ray of the cervical spine (two views) is taken today and reveals straightening of the normal lordosis. 3) An x-ray of the lumbar spine (two views) is taken today and is normal. 4) An x-ray of the right shoulder (two views) is taken today and is normal. 5) An x-ray of the right wrist (two views) is taken today and is normal. 6) An x-ray of the left wrist (two views) is taken today and is normal. 7) An x-ray of the right hand (two views) is taken today and is normal. 8) An x-ray of the left hand (two views) is taken today and is normal. Special Diagnostic Testing: 1) A pulmonary function test is performed revealing an FVC of 0.80 L (23.0%), an FEV 1 of 0.64 L (23.2%), and an FEF of 0.61 L/s (23.1%). There was no change after the administration of Albuterol. 2) A 12-lead electrocardiogram is performed revealing sinus rhythm and a heart rate of 71 per minute. 3) A pulse oximetry test is performed today and is recorded at 97%. Laboratory Testing: A random blood sugar is performed today and is recorded at 97 mg/dL. The urinalysis performed by dipstick method was reported as 3+ blood and 1+ protein. Subjective Complaints: 1) Headaches. 2) Dizziness. 3) Lightheadedness. 4) Visual difficulty. 5) Cough. 6) Throat pain. 7) Jaw pain. 8) Jaw clenching. 9) Dry mouth. 10) Chest pain. 11) Palpitations. 12) Shortness of breath. 13) Abdominal pain. 14) Burning symptoms. 15) Reflux symptoms. 16) Nausea. 17) Diarrhea alternating with constipation. 18) 15 pound weight gain. 19) Urinary frequency and urgency. 20) Sexual dysfunction. 21) Cervical spine pain. 22) Thoracic spine pain. 23) Lumbar spine pain. 24) Bilateral shoulder pain. 25) Bilateral elbow pain. 26) Bilateral wrist pain. 27) Bilateral hand pain and numbness. 28) Bilateral hip pain. 29) Bilateral knee pain. 30) Bilateral ankle pain.

31) Bilateral foot pain and numbness. 32) Peripheral edema and swelling of the ankles. 33) Anxiety. 34) Depression. 35) Difficulty concentrating. 36) Difficulty sleeping. 37) Difficulty making decisions. 38) Forgetfulness. 39) Hair loss from the scalp. 40) Dermatologic complaints. 41) Intolerance to excessive heat and cold. 42) Diaphoresis. 43) Chills. 44) Lymphadenopathy. Objective Findings: 1) Frontal scalp reveals scarring along with raised patches of hyperpigmented lesions. 2) Hyperpigmented regions of the bilateral upper extremities and chest. 3) TMJ tenderness bilaterally. 4) Abdominal bloating. 5) Epigastric tenderness. 6) Right lower quadrant tenderness. 7) Tenderness and myospasm of the cervical, thoracic and lumbar paraspinal musculature. 8) Tenderness of the bilateral shoulders, biceps and triceps. 9) Tenderness of bilateral elbows. 10) Tenderness of bilateral forearms. 11) Tenderness of bilateral wrists and hands. 12) Tinel's is positive bilaterally. 13) Tenderness of bilateral hips. 14) Tenderness of the quadriceps muscles of the knees, calves and ankles. 15) A pulmonary function test revealing an FVC of 0.80 L (23.0%), an FEV 1 of 0.64 L (23.2%), and an



FEF of 0.61 L/s (23.1%). There was no change after the administration of Albuterol. 16) A 12-lead electrocardiogram revealing sinus rhythm and a heart rate of 71 per minute. 17) A pulse oximetry test is recorded at 97%. 18) A random blood sugar is recorded at 97 mg/dL. 19) The urinalysis was reported as 3+ blood and 1+ protein. Diagnoses: 1) Musculoskeletal injuries involving cervical, thoracic and lumbar spine, bilateral shoulders, elbows, wrists, hands, hips, knees, ankles and feet. 2) Cervical spine sprain/strain. 3) Cervical spine stenosis. 4) Multilevel cervical spine disc disease. 5) Thoracic spine sprain/strain. 6) Lumbar spine sprain/strain. 7) Tendinosis bilateral shoulders. 8) Epicondylitis bilateral elbows.

9) Bilateral wrist sprain/strain. 10) Tendinosis bilateral hips. 11) Tendinosis bilateral knees. 12) Bilateral ankle sprain/strain. 13) Hyperlipidemia (2021). 14) Hypothyroidism (2012). 15) Pulmonary nodule x 2 (4 mm lingula and 3 mm left lower lobe). 16) Scaring of the frontal scalp region. 17) Rule out autoimmune skin condition. 18) Headaches. 19) Chronic headaches. 20) Dizziness/lightheadedness. 21) Rule out visual disorder. 22) Cough/throat pain. 23) TMJ syndrome. 24) Bruxism. 25) Xerostomia. 26) Chest pain. 27) Heart palpitations. 28) Shortness of breath secondary to asbestos exposures. 29) Gastritis/GERD secondary to NSAID medications. 30) Nausea. 31) Irritable bowel syndrome manifested by diarrhea alternating with constipation. 32) Urinary frequency and urgency. 33) Sexual dysfunction. 34) Peripheral edema/swelling of ankles. 35) Anxiety disorder. 36) Depressive disorder. 37) Sleep disorder. 38) Difficulty with concentration. 39) Difficulty with decision making. 40) Forgetfulness. 41) Alopecia. 42) Chills. 43) Diaphoresis. 44) Lymphadenopathy. 45) Allergy to penicillin. Discussion: The patient worked for JP Morgan Chase for the past 32-33 years as a branch manager. She was responsible for all operations within the bank. When she initially started in 1988, she was working as a teller and then was promoted to manager in 2000. Part of her management duties was to maintain staffing and the cash handling. Her branch was short of staff, therefore, this caused her significant stress as she had to cover all the duties required by other employees. She would often have to lift bags of coins or cash that weighed more than 50 pounds at times. She also mentions that she performed repetitive bending, stooping and handling of currency. In 2018, the patient relates that she began to be bullied at the workplace, as she continued to request more employees.

Despite her requests, additional employees were being transferred from her branch to other locations. She was also moved to different location that was heavily understaffed and had management problems. The patient relates that she began to develop “brain fog” and hand numbness in 2018-2019. In January 22, 2020, she was no longer able to continue performing her job duties due to the stressful environment at the workplace. She does mention that during 2019, she developed a skin condition which affected her forehead, facial region, upper extremities and back region. She did undergo skin biopsy which was negative. She is off work at this time. She now complains of continued skin irritation, headaches, acid reflux, anxiety and depression and she has gained approximately 15 pounds weight. She also complains of musculoskeletal pain throughout her entire body. It has to be noted that the listed diagnoses represent medical diagnoses

and/or a differential diagnosis to a reasonable degree of medical probability based on the history provided to this examiner by the patient and the findings of his examination. He believe that some of these diagnoses are industrial in origin and are either initiated or aggravated by the patient's employment and are, therefore, industrial in origin. Some diagnoses are non-specific and will require further evaluation. Treatment authorization, if already approved, is appreciated. If treatment has not yet been approved, it is hereby requested. The various diagnoses listed appear to be consistent with the type of work that would typically cause such abnormalities. This examiner, therefore, believe that the diagnoses listed thus far are AOE/COE. Disability Status: The patient is to continue on temporary and total disability for a period of six weeks. Treatment: She is to continue with her current medications. She is prescribed Lansoprazole 15 mg daily, Flurbiprofen topical cream to apply biweekly and Fluocinonide 0.15% to apply twice a week. She will be reevaluated in six weeks.

58) March 29, 2022 (DOE), April 26, 2022 (DOR), PQME in Internal Medicine Comprehensive Medical-Legal Report, Stewart Lonky, MD: DOI: CT: 05/17/18-05/18/19. HPI: The patient relates that she began working for Great Western Bank on December 27, 1988 as a teller. Five months later, she was promoted to a banker. During her banking career, she relates that she was involved in nine robberies, either take-over of the bank robberies or one-on-one robberies. In 1993, she worked at the Venice Branch. After the 1992 Northridge Earthquake, there was a lot of damage to the building. There was a lot of rain and the roof fell in. During construction, the office was not closed. She was exposed to dust and particulate matter from the debris. With working in this environment, she began to have a dry cough. She worked at the Venice Branch from 1993 to 1994. During the year she worked there, she had bronchitis twice. From October 1994 to April 1995, she returned to work at the Torrance-Del Arno Branch due to her being involved in two take-over robberies while at the Venice Branch. While she was at the Torrance-Del Arno Branch, she was exposed to dust and particulate matter during a remodel with the bank remaining open. She recalls continued bouts of bronchitis and more frequent colds. In 1995, she moved to Florida and worked at a Great Western Bank in Florida. That year she had a very bad bout of bronchitis. In 1997, Great Western Bank was bought out by Washington Mutual Bank. She worked as a banker until August 2000. As a banker, she was responsible for opening new accounts, assisting at the teller line, marketing the bank outside, making sales calls, helping tellers with referrals, loading money into the ATMs, helping in the vault, doing cash audits, providing customer service such as fraud maintenance on accounts, referring products to customers, cross selling and processing mortgages, referring customers for investment accounts and doing customer fixed-annuity accounts.

She would open and close the branch, depending on who the manager was. She was licensed in California Life and Health and Life Insurance. In August 2000, she was promoted to branch manager while employed by Washington Mutual Bank. She worked at several branches as a banker and as a branch manager. As a branch manager for Washington Mutual Bank, she was assigned to smaller branches with fewer employees. Thus, she was responsible for opening and closing the bank, as well as performing banker

duties such as teller and new account duties, depending on the branch. At one point, while working for Washington Mutual Bank, she was assigned an assistant branch manager. This freed her to hire and coach employees, and increase employee productivity. At Washington Mutual Bank, as a branch manager, she worked on a reward system. She was rewarded on the net profitability of the bank, including the banking, investments, customer service and productivity of her employees. If her branch performed well, she would receive monthly bonuses. From 2007 to 2008, she worked at the Century City Branch. In 2008, Washington Mutual Bank was bought out by JP Morgan Chase. While at JP Morgan Chase, she would work at a branch in Florida. While working for both Washington Mutual Bank and even more so at JP Morgan Chase, she dealt with money while using machine money counters. The process of the money going through the machines produced a lot of fibers and dust. She had to use a blower to clean out the machines, which kicked up even more dust. With performing all of these duties and with exposure to dust, she would sneeze, have nasal congestion and cough. She would take Benadryl. In 2009, she was prescribed Flonase as well. She relates that she continued working as a branch manager but the company culture and rules changed drastically under JP Morgan Chase. Monetarily, the reward system changed.

She was given a slight increase in her base salary, but the reward system changed such that she was rewarded only annually and the bases for these awards changed. Regarding her duties under JP Morgan Chase, branch managers were trained on the sales side; assistant managers were trained on the teller side. She relates that throughout her tenure as a banker and branch manager, there were inherent stressors with which she had to endure; however, it was at this point, with the purchase by JP Morgan Chase Bank that everything worsened exponentially. First, a branch manager and peer, Diana Nielson, who had worked with Washington Mutual Bank was promoted to market director with the buyout by JP Morgan Chase Bank, placing her as the patient's supervisor. She had been considered by the previous market director to be the branch manager in Culver City, which provided a promotion opportunity for the patient. However, when Diana Nielson became her manager, she was transferred to the Hawthorne Branch instead. Later, the patient became aware that she had done this for two main reasons: to quell her promotion opportunity and she was "not the right color" for the branch. At that point, she was transferred to the Hawthorne Branch and was trained on the new job duties and expectations of JP Morgan Chase. This was considered a Hispanic-designated office. As such, it was difficult for her because she did not speak the language and had to have an interpreter often to assist customers. She relates that the Hawthorne Branch was very transactional and was not as profitable. It had a lot of losses due to fraud and there were not a lot of deposits.

This caused her stress because she was not able to make any bonuses under the new reward structure for two years. While she was at the Hawthorne Branch for five and one-half years, first Diana Nielson removed the assistant manager to another branch without her knowledge; she replaced one and then fired them; and finally then her assistant manager position was removed. With not having an assistant manager, this greatly increased her workload. Also, she had not been trained on the assistant manager's duties.

Also, at the Hawthorne Branch, she had a take-over robbery, wherein four-to-five men took over the bank. During all of the turmoil and stress, she relates that she had great employee support, which was recognized; however, her relationship with Diana Nielson worsened. She would have “hour-long” counseling sessions on what she perceived the patient had done incorrectly, but she would not recognize the patient’s successes. Gradually, she became very “jumpy” because she felt as though her supervisor was ready to pounce. She became anxious and depressed. She had difficulty sleeping and eating. The stress became so untenable that she felt as though she wanted to move from that branch or out of the state. As a result, as early as 2008, she began to feel significant cramping pain in her stomach, with bouts of alternating constipation and diarrhea as well as epigastric burning. She relates that it felt as though she were having a heart attack. As a result of her symptoms, she presented to her primary care physician at Kaiser Permanente Medical Group. Gastroesophageal reflux disease was diagnosed, and Prevacid was prescribed. Her hair began to fall out.

Diana told her that she had to do something with her hair because it looked strangely. She relates that Diana conducted monthly meetings. During a monthly meeting, she was blamed for a mistake that was committed while she was on vacation. In front of the patient’s peers and managers from other departments, Diana told her that she would give her the status of her job later in the day. She felt that she was being belittled in front of her peers and could be fired potentially, in addition to being blamed for something that had occurred while she was on vacation. Due to working long hours, lifting heavy bags of cash and coin, standing to work in very long teller lines without having been trained, and extensive computer work, progressively, she experienced the onset of neck pain, radiating to her upper extremities; swelling of her hands; mid-back pain; low back pain, radiating to her legs; and numbness of her mouth. She had significant changes in her menstrual cycle, as well. Gradually, she experienced intense headaches. Initially, she took over-the-counter medication; however, when they persisted, she presented to Kaiser. Tension headaches were diagnosed and Topamax was prescribed. Also, Diana and her boss conducted monthly business reviews of the branches. During these meetings, Diana and her boss put her down in front of her peers. She felt belittled, criticized, and demeaned. She was extremely embarrassed. She began to feel as though she were “nothing, a bad person!” In 2011, she consulted her primary care physician who diagnosed hypothyroidism. Levothyroxine was prescribed. For the musculoskeletal symptoms, in 2012, she was referred for physical therapy.

Moreover, during her tenure at the Hawthorne Branch, Diana put people at the branch to try to get her employment terminated. In September 2013, a former supervisor who had known her work ethic; got her transferred to the West Los Angeles Branch. From September 2013 to December 2013, Diana insisted that she travel between the Hawthorne Branch and West Los Angeles Branch, a one- and-one-half hour commute to help the failing Hawthorne Branch, once she left. For musculoskeletal pain, she took anti-inflammatory medications, such as Ibuprofen, naproxen and Mobic, as well as Flexeril. She could no longer handle driving from home to West Los Angeles, and transferred to the Redondo Beach Branch in August 2014. She worked there until August 2015. She

continued to have a work overload with increased stress and musculoskeletal symptoms due to the office being very understaffed. From October 2015 to August 2017, she worked in Florida. She was tasked with finding old collateral for Chase marketing (merchandise, posters, etc.). She had to look under desks, in closets, behind HM areas and security areas that were never cleaned. In this search, she was exposed to substantial amounts of dust and dust from old crumbling ceiling tiles. Her clothes would be filled with dust. She had difficulty breathing, a runny nose, and nasal congestion, as a result of working in this environment. With lifting and moving objects around, she began to feel increased neck, bilateral shoulder, and back pain, as well as numbness in her hands and feet. She felt pain over her chest that was in part muscular and in part pressure in her chest. At the end of the year, she took a six-week leave of absence due to her symptoms. She sought medical treatment and was diagnosed with chronic pain, disc degeneration and acute stressors.

After her leave of absence, she was reassigned as a floater branch manager to 13 different offices, checking for the previously described old merchandise and covering for managers. Gradually, when working in the Florida branches, she felt increased headaches and musculoskeletal pain, as well as symptoms of colds and bronchitis. In April 2018, she relates that she consulted her Kaiser physician, an upper respiratory infection was diagnosed and antibiotics were prescribed. In May 2018, she was assigned to the Beverly Center Branch with Kathy being her market director. She indicates that the hostile work environment persisted under Kathy. At the beginning of January 2019, she was working at the Beverly Center Branch and Kathy removed her because it became a combined branch. She would have been paid more to run that branch. Kathy put someone at that branch whom she favored. The patient was moved to a poorly performing branch, the Fairfax Branch office. She had to “scrub” the office, and found documents from 1993. Ultimately, she was blamed for the documents being there. She worked longer hours due to the branch being short-staffed and poor performing. She endured further weekly harassment by Kathy who came to the branch weekly and would reprimand her in front of her employees. On January 28, 2019, as she was driving to work and began to work, she began to feel chest pain and pressure. She became dizzy. She felt numbness and tingling in her hands and feet and it looked like her bones were sticking out of her hands. Kaiser Medical Advice advised that she go to the emergency room. She was transported by paramedics to Kaiser Medical Center Emergency Department. She was worked up for blood clots and a stroke. Anxiety was diagnosed ultimately. She last worked on March 15, 2019.

Present Complaints: She last worked on March 15, 2019. She retired on September 01, 2021 because they could no longer hold her job. After she left work, she began to have skin problems over her entire face, with extra skin. She saw six different dermatologists through Kaiser with varying diagnoses. She was treated for her musculoskeletal symptoms by a physical medicine specialist for Kaiser. She continued to feel neck pain and difficulty swallowing. In 2020, she had a CT scan of her chest that showed two nodules, 2 mm and 3 mm, on her left lung. Since that time, she has been scheduled for annual CT scans. Now she has episodes of chest pressure and tightness that worsen at

night. She coughs at night. She awakens gagging in her sleep. She states that when she feels sick, she can wheeze badly. She has never had mold or allergy testing. She has nasal congestion that drains into both ears, left greater than right. She feels that her left ear is completely clogged. She was diagnosed with diverticulitis three years ago after a colonoscopy. Also, a hole was found in a pocket of her right intestines. She had difficulty digesting her food. She had to change her diet. She is not able to eat nuts. Regarding her stomach, she still experiences pain and cramping of her stomach, more on the right side. She has a lot of acid reflux. She takes Prevacid with partial benefit. She is more constipated. She has not had an endoscopy. She began seeing a workers' compensation physician, Dr. Daldalyan, at Del Carmen Medical Center, who became her primary treating physician. She was placed on temporary total disability. He gave her an Albuterol inhaler. She uses it every other day when short of breath. She becomes short of breath with exertion, mostly. She had seen referred to psychologists through the workers' compensation system. She is seeing a therapist in group sessions at Kaiser, now weekly. On a monthly basis, she is followed by a therapist.

For her musculoskeletal, she sees Dr. Helen Chung, a physical medicine specialist at Kaiser. She has been referred to acupuncture. She is keeping her off work. She relates that her quality of life has been greatly diminished given her protracted musculoskeletal, respiratory, gastrointestinal and psychological symptoms. Regarding her activities of daily living, she has difficulty cooking due to prolonged standing and dropping items due to her hand symptoms; she is unable to clean her home; she has difficulty lifting groceries greater than five pounds; she has difficulty driving. Occupational History: The patient commenced employment on December 27, 1988. Initially, she was hired by Great Western Bank, which was bought out by Washington Mutual in 1997. In turn, JP Morgan Chase bought out Washington Mutual in 2008. She worked as a banker and branch manager. Past Medical History: In 2011, she was diagnosed with hypothyroidism. Medications: Albuterol inhaler, Prevacid, levothyroxine, Cymbalta, Mobic, Flexeril. Family History: Her father is 77-years-old; her mother is 75-years-old. She has 1 sister, age 50; she has 1 brother, age 40. There is a family history of hypertension through her mother, father and sister; a stroke through her father; diabetes through her father; a respiratory condition through her sister (nasal allergies); and cancer through her paternal grandmother (breast). Social History: She is married with 1 daughter - age 18; 1 son - age 24. She lives with her husband and family. Habits: Tobacco: She is a non-smoker. Alcohol: Once or twice a week, she drinks a glass of wine. Review of Records: Dr. Lonky reviewed the patient's medical/nonmedical records dated from 05/06/2008 to 10/28/21. Diagnoses: 1) History of employment as a bank branch manager for JP Morgan Chase and its predecessors, commencing in 1988 when she worked for Great Western Bank.

2) History of multiple musculoskeletal complaints including cervical spine, bilateral carpal tunnel, and other musculoskeletal pain. Deferred to specialist in orthopedics and pain management. 3) History of severe qualitative and quantitative work overload as demonstrated in the medical records and history with frequent travel, and long-term absence from her family in California. 4) History of interpersonal relationship

difficulties with immediate supervisor causing stress in the workplace, deferred to specialist in Psychiatry. 5) Chronic anxiety and depression, intensified secondary to pain. 6) Longstanding and long-term use of nonsteroidal antiinflammatory drugs for musculoskeletal pain. 7) History of gastritis and gastroesophageal reflux disease dating back to at least 2012. 8) Recent increase in gastrointestinal problems including irritable bowel syndrome with constipation initially starting out as mixed irritable bowel syndrome with diarrhea and constipation. 9) History of diverticulosis. 10) History of exposure to dusts in the workplace, with complaints of shortness of breath but no evidence of reactive airways disease or restriction. 11) Deviated nasal septum. 12) Probable chronic rhinitis, partially allergic and partially secondary to anatomic abnormalities in her nasal passages. 13) Longstanding history of eczema, with non-definable specific allergies. 14) History of hypothyroidism secondary to thyroiditis, non-industrial. Impressions and Discussion: This examiner has had the opportunity to evaluate the patient in his role as a Panel Qualified Medical Evaluator in internal medicine. Hers is a very complicated and complex history, and this examiner is somewhat surprised at the dates of the continuous trauma claim ranging from 2018 to 2019, particularly as it pertains to her gastrointestinal problems.

As he reviews all of her medical records and her history, her complaints of upper extremity difficulties, eventually being diagnosed as carpal tunnel syndrome, began in the mid-2000s. She has been treated with meloxicam (Mobic) since that time, being switched, on occasion, to other nonsteroidal antiinflammatory drugs for the treatment of this problem. Since the time she was started on these medications, there have been complaints of gastroesophageal reflux disease, with many of her Kaiser appointments noting that instructions were given to the patient in order to minimize and mimic the severity of her GERD. There is no question that the use of nonsteroidal antiinflammatory drugs over a long period of time can result in gastric problems, particularly hyperacidity, contributing to the development of reflux esophagitis. There are numerous articles in the literature showing that patients on chronic NSAID therapy clearly have a high incidence of both gastritis, gastric ulcer, and reflux problems with esophagitis. In addition to the use of nonsteroidal antiinflammatory drugs, there has been a significant amount of emotional stress, as uncovered in the history this examiner obtained from the patient as well as in the medical records and notes from various psychologists and psychiatrists. The difficulty that she had with her supervisor, the requirement for travel to Florida away from her family, the frequent traveling within Florida and then back to California took a toll on her and her family relationships. She is not a specialist in the field of psychiatry, but it is clear from all of the notes that this examiner has reviewed that this subjected her to significant amount of anxiety, depression, and emotional stress. The medical literature is fairly straightforward as far as the gastrointestinal complications that are associated with emotional stress. One of these problems is the development of gastric hyperacidity, dyspepsia, heartburn, and reflux.

In this examiner's opinion, with reasonable medical probability, her development of upper gastrointestinal problems can be attributed to the combination of her emotional stress as well as the use of nonsteroidal anti-inflammatory drugs. As far as her lower

gastrointestinal tract, the same literature that this examiner has referred to above has shown that one of major consequences of chronic emotional stress is the development of an irritable bowel syndrome. Although this patient has a history of diverticular disease, this examiner cannot find any evidence of her having acute diverticulitis. Rather, it appears that initially with intermittent diarrhea and constipation, she has now been relegated to what is frequently called IBS-C or irritable bowel syndrome with constipation. This irritable bowel is known to be a consequence of chronic emotional stress from either pain or from other causes of stress such as the patient experienced. From a respiratory perspective, there is a deviated septum, and this leads to complications, which have nothing to do with exposures to any dusts, fumes, smoke, or contaminants in the air. Although she worked in older buildings, and was exposed there various dusts, there is no evidence of there being any allergic reaction to any mold or other dusts including dust mites. It is this examiner's opinion that both her upper and lower respiratory tract issues are a result of her deviated septum, and are not industrially related. Disability: This examiner indicates that he will defer comments regarding orthopedic and psychiatric factors of disability to the appropriate specialists. From an internal medicine perspective, it is his opinion that she has an upper gastrointestinal impairment according to Table 6-3 in AMA guides that falls into a Class 2 impairment. She has not been managed well on diet alone and clearly needs medical therapy.

This qualifies her for Class 2 impairment rather than a Class 1 impairment and it is this examiner's opinion that a 10% whole person impairment rating is appropriate. It appears, at this time, that this is at maximum medical improvement. With regard to her lower gastrointestinal tract, this examiner has utilized Table 6-4 in AMA guides to classify her irritable bowel syndrome with constipation. It is his opinion that a Class 1 impairment with a 5% whole person impairment rating is appropriate for her. This is also at maximum medical improvement for rating purposes. Causation and Apportionment: As discussed above, it is this examiner's opinion that both her upper and lower GI issues are industrially related, due to the contributions of stress and from the use of NSAIDs. With regard to her upper respiratory symptoms, it is his opinion that they are non-industrial, related to her deviated nasal septum and its complications. He added that he will defer any comments from a psychiatric or orthopedic perspective to the appropriate specialists in these areas. With regard to apportionment, he believes that with reasonable medical probability her upper GI disability related to her impairment should be apportioned 100 percent to industrial causation with regard to the lower GI tract, there were stressors outside the workplace, as noted by psychiatric consultants, and this examiner would apportion 50 percent of the corresponding disability to non-industrial causes and 50 percent to industrially related stresses, including poor interpersonal relationships, qualitative work overload, hectic travel, and her ongoing pain. Work Restrictions: Any work restrictions in this patient are orthopedic and/or psychiatric in nature. This examiner defer comments to the appropriate specialists.



**Eric E. Gofnung Chiropractic Corp**

6221 Wilshire Blvd Suite 604  
Los Angeles, CA 90048  
United states

Phone (323)933-2444  
Fax (323)933-2909

Important Notice: This report contains protected health information that may not be used or disclosed unless authorized by the patient or specifically permitted by the Health Insurance Portability and Accountability Act (HIPAA).

\_\_\_\_\_  
Evaluator

\_\_\_\_\_  
Date

## Summary/Discussion

### Calibration Certificate

| Date of Examination | Device Type   | Device ID |
|---------------------|---------------|-----------|
| 8/8/2022            | Muscle Tester | 19EE89    |

#### Last Factory Calibration

| Date      |
|-----------|
| 5/28/2014 |

#### Last Full Calibration

| Date & Time          | Drift from Factory Calibration | JTECH Recommended Drift Limits |
|----------------------|--------------------------------|--------------------------------|
| 1/20/2021 3:59:10 PM | 2.0%                           | ±20%                           |

#### Last Zero Calibration

| Date & Time          | Drift from Factory Calibration | JTECH Recommended Drift Limits |
|----------------------|--------------------------------|--------------------------------|
| 1/20/2021 3:59:10 PM | 2.0%                           | ±20%                           |

## Patient Information

**Name:** Sandra Seeram  
**Gender:** Female  
**Birth Date:** 11/19/1968  
**Dominant Hand:** Right

**Primary Insurance**

**Secondary Insurance**

**Employer**

**Referral**

**Attorney**

**Care Providers**

**Range of Motion - Inclinometry**

**Spine Range of Motion**


The patient's active range of motion was objectively evaluated with Tracker ROM from JTECH Medical using the dual inclinometry protocols outlined in the AMA Guides to the Evaluation of Permanent Impairment.

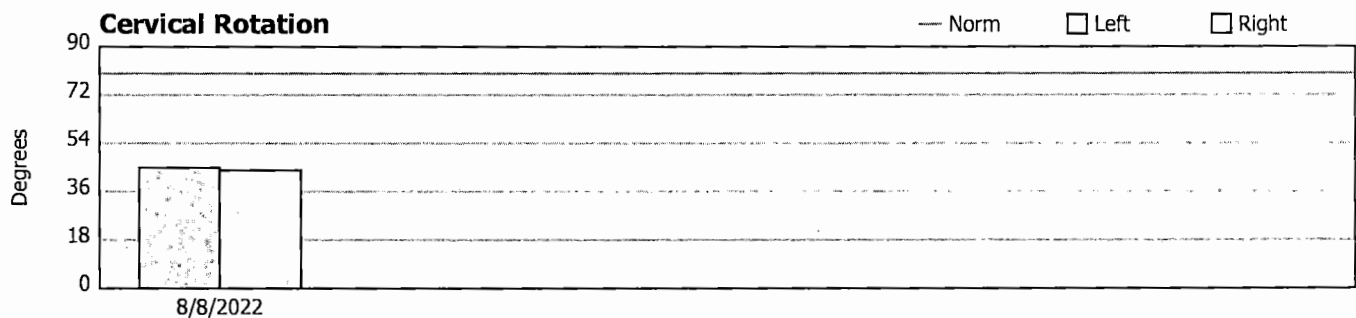
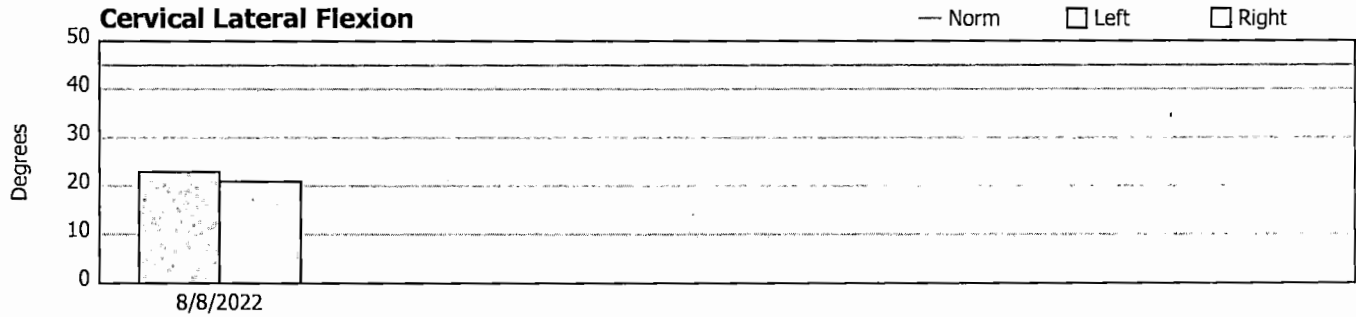

| Cervical ROM            | Norm | Result | Difference | % Norm |
|-------------------------|------|--------|------------|--------|
| Cervical Flexion        | 50°  | 26°    | 24°        | 52%    |
| Cervical Extension      | 60°  | 31°    | 29°        | 52%    |
| Cervical Lateral Left   | 45°  | 23°    | 22°        | 51%    |
| Cervical Lateral Right  | 45°  | 21°    | 24°        | 47%    |
| Cervical Rotation Left  | 80°  | 45°    | 35°        | 56%    |
| Cervical Rotation Right | 80°  | 44°    | 36°        | 55%    |

According to the AMA Guides, "An accessory validity test can be performed for lumbosacral flexion and extension... If the straight-leg-raising angle exceeds the sum of sacral flexion and extension angles by more than 15°, the lumbosacral flexion test is invalid. Normally, the straight-leg-raising angle is about the same as the sum of the sacral flexion-extension angle... If invalid, the examiner should either repeat the flexion-extension test or disallow impairment for lumbosacral spine flexion and extension."

Unless otherwise noted, the table(s) above show current test results compared to American Medical Association normative values.

**Spine Range of Motion Progress**





**Custom Spine Range of Motion**

The patient's active range of motion was objectively evaluated with Tracker ROM from JTECH Medical using dual inclinometry protocols.

**Custom Spine Range of Motion Progress**

**Extremity Range of Motion**

The patient's active range of motion was objectively evaluated with Tracker ROM from JTECH Medical using the single and dual inclinometry protocols outlined in the AMA Guides to the Evaluation of Permanent Impairment.

The table(s) above show current test results compared to American Medical Association normative values.

**Extremity Range of Motion Progress**

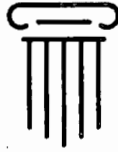**Custom Extremity Range of Motion**

The patient's range of motion was objectively evaluated with Tracker ROM from JTECH Medical using single and/or dual inclinometry protocols.

**Custom Extremity Range of Motion Progress**

# WORKERS DEFENDERS LAW GROUP

751 S Weir Canyon Rd Ste 157-455  
Anaheim CA 92808  
Tel: 714 948 5054  
Fax: 310 626 9632  
workerlegalinfo@gmail.com  
www.workerlegal.com



Natalia Foley, Esq  
Principal Attorney  
Tel: 310 707 8098  
nfoleylaw@gmail.com  
UAN: WORKERS DEFENDERS ANAHEIM  
ERN: 13792552

TO: ERIC E. GOFNUNG CHIROPRACTIC  
CORPORATION  
6221 WILSHIRE BLVD., SUITE 604  
LOS ANGELES, 90048  
Tel 323-933-2444  
Scheduling@Gofnung.com

CC: OD LEGAL  
355 S. GRAND AVE STE 1400  
LOS ANGELES CA 90071

SIBTF  
1750 Howe Avenue, Suite 370  
Sacramento, CA 95825-3367  
Tel 916 928 4601/ fax 916 928 4705

RE: SANDRA SEERAM vs JP MORGAN CHASE  
WCAB: ADJ12217188 (DOI: 05/17/2018 - 05/18/2019)  
SIBTF: SIF12217188

DATE: 6/2/2022

## COVER LETTER FOR SIBTF MEDICAL EVALUATION

### DEAR Dr. ERIC E. GOFNUNG:

This office represents the above referenced applicant. You have been selected to act in the capacity of Medical Evaluator in regard to the applicant's Subsequent Injury Benefit Trust Fund Claim in your medical specialty.

You are specifically asked to provide a medical legal evaluation in your area of expertise. Please provide a medical legal evaluation and address the issue of causation of any injury within your area specialty.

Please provide your opinion if any other referral is necessary.

It is requested that a determination be made regarding any medical issues and disability within your area of specialty. Please provide a permanent impairment rating per the AMA guides 5<sup>th</sup> edition and address the issue of apportionment per LC section 4751 in regard to a particular period of time as follow:

- 1) **PRE-EXISTING CONDITION**
- 2) **SUBSEQUENT INJURY**
- 3) **CURRENT CONDITION** (post-industrial).

### Please cover in your report the following topics:

- Subjective complaints
- Objective factors or findings
- Current diagnosis and impairment rating

- Occupational history
- Past medical history
- Prior injuries
- Pre-existing **labor disabling** condition
- Rating of pre-existing labor disabling conditions
- History of subsequent injuries
- Impairment rating of subsequent injuries
- Subsequent injuries causation
- Apportionment of current condition to pre-existing and subsequent injuries
- Disability status & permanent work restrictions if any
- Activities of daily living

**PLEASE ANSWER THE FOLLOWING QUESTIONS WITHIN THE SCOPE OF YOUR SPECIALTY:**

1. On the day of your evaluation does the worker have a permanent impairment of any body parts **within your specialty?**
2. **IF YES**, is the worker 'condition permanent and stationary as of today?
3. **IF YES**, what is this impairment rating as of today, the date of your evaluation?
4. What kind of current work restrictions worker has due to his permanent impairment?
5. Did worker have a preexisting condition **within the scope of your specialty?**
6. **IF YES**, please answers the following questions:
  - (a) Was that preexisting condition partially labor disabling and could have been rated as permanent partial disability ("PPD") at the time worker suffered the subsequent industrial injury?
  - (b) Was that preexisting condition aggravated during the time of the subsequent employment?
  - (c) Did worker have a subsequent injury within the scope of your specialty?
  - (d) Did the subsequent industrial injury result in additional PPD?
7. Please APPORTION worker's condition as of today to the following:
  - (a) pre-existing condition
  - (b) subsequent injury
  - (c) post-subsequent injury
8. Is the combination of the preexisting disability and the disability from the subsequent industrial injury greater than that which would have resulted from the subsequent industrial injury alone?
9. Did the subsequent industrial injury rate to a 35% disability without modification for age and occupation:
  - (a) within the scope of your specialty?

- (b) within the multidisciplinary combined rating (if known)?
10. Did the pre-existing disability affect an upper or lower extremity or eye?
  11. Did the subsequent industrial permanent disability affect the opposite or corresponding body part?
  12. Is the total disability equal to or greater than 70% after modification?
    - (a) within the scope of your specialty?
    - (b) within the multidisciplinary combined rating (if known)?
  13. Is the employee 100% disabled or unemployable from other pre-existing disability and subsequent injuries together?
    - (a) within the scope of your specialty?
    - (b) within the multidisciplinary combined rating (if known)?

#### **RATING DETERMINATION:**

When you rate pre-existing condition, please remember, that the prior labor disabling disability is not rated separately in the SIBTF case. SIBTF liability is not determined by rating the prior disability alone.

The percentage of permanent disability from the prior disability is not a relevant factor in determining SIBTF eligibility [Subsequent Injuries Fund v. Industrial Acc. Com. (Harris) (1955) 44 Cal. 2d 604, 608, 20 Cal. Comp. Cases 114, 283 P.2d 1039].

Rather, the factors of disability or WPI from the prior disability are rated together with those from the subsequent industrial injury to produce the combined disability rating required by Labor Code section 4751

#### **PRE-EXISTING DISABILITY DISCUSSION**

Please note that prior labor disabling disability is rated as it exists at the time of the subsequent industrial injury; and the apportionment statutes applicable in an industrial injury case do not establish prior labor disabling disability in an SIBTF case. However the apportionment is important for the analysis of the combined degree of disability,.

Thus it is important that in your discussion of pre-existing disability and its labor disabling nature please discuss the following issues:

- Whether an applicant have been “permanently partially disabled” at the time of a subsequent industrial injury and if yes, please indicate which prior evidence show that non-industrial prior labor disabling disability had achieved permanency at the time of the subsequent industrial injury.
- Whether prior disability have impacted the applicant’s ability to work in a **demonstrable way**, and if yes - please describe whether these limitations resulted or could result for applicant in loss of wages, change in jobs, and/or change in work duties or abilities and other impact of the applicant’s ability to work.

#### **DISCUSSION OF SUBSEQUENT INDUSTRIAL INJURY**



Please note that per *Brown v. Workers*, a finding and award or a stipulated award is not necessary to prove the compensability of the industrial case, thus in SIBTF case your opinion about compensability of the subsequent injury is important.

Please note further, that for the purposes of SIBTF case, a C&R does not necessarily establish any fact in a case. C&R in the regular benefits case neither proves nor disproves compensability, nor does it prove any level of disability. Thus, you are expected to provide an impairment **rating within your specialty as of the date of the evaluation** and provide your opinion as to the apportionment to pre-existing conditions, subsequent industrial injury and post-subsequent industrial injury

Finally, it is expected that you would provide your answer to the following important questions:

- WHETHER THE DEGREE OF DISABILITY FROM PRIOR DISABILITY AND SUBSEQUENT INJURY COMBINED IS GREATER THAN THAT FROM SUBSEQUENT INJURY ALONE,  
*and*
- WHETHER SUBSEQUENT COMPENSABLE INDUSTRIAL INJURY RESULTING IN ADDITIONAL PERMANENT DISABILITY

In order to facilitate your evaluation, we provide medical records for the above applicant in our possession according to the exhibit list attached.

If you need any additional testing, please advise so.

If you believe that the applicant has health issues outside of your specialty, please defer these issued to the medical doctors of appropriate specialty, please indicate what specialty is recommended.

Thank you for your anticipated courtesy and cooperation herein.

Very truly yours,



By Natalia Foley, Esq  
WORKERS DEFENDERS LAW GROUP

MEDICAL RECORDS ARE HERE:

<https://nataliafoleylaw.com/01%20-%20SANDRA%20SEERAM.html>

## PROOF OF SERVICE

1. I am over the age of 18 and not a party of this cause. I am a resident of or employed in the county where the mailing occurred. My residence or business address is  
751 S Weir Canyon Rd Ste 157-455  
Anaheim CA 92808

2. I served the following documents:

### COVER LETTER FOR SIBTF EVALUATION


---

by enclosing a true copy in a sealed envelope addressed to each person whose name and address is shown below and depositing the envelope in the US mail with the postage fully prepaid.

- Date of Mailing: 9/4/2021
- Place of Mailing: Los Angeles, CA

3. I declare under penalty of perjury under the laws of the State of California that the foregoing is true and correct.

Date: 9/4/2021



By Irina Palees, Legal Assistant  
to Attorney Natalia Foley

### Name and Address of each Person to whom Notice was Mailed

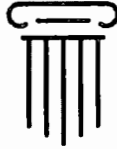WCAB (AHM)  
1065 N PACIFIC CENTER DR  
STE 170  
ANAHEIM CA 92806

OD LEGAL  
355 S. GRAND AVE STE 1400  
LOS ANGELES CA 90071

SIBTF  
1750 HOWE AVENUE, SUITE 370  
SACRAMENTO CA 95825-3367

# WORKERS DEFENDERS LAW GROUP

751 S Weir Canyon Rd Ste 157-455  
Anaheim CA 92808  
Tel: 714 948 5054  
Fax: 310 626 9632  
workerlegalinfo@gmail.com  
www.workerlegal.com



Natalia Foley, Esq  
Principal Attorney  
Tel: 310 707 8098  
nfoleylaw@gmail.com  
UAN: WORKERS DEFENDERS ANAHEIM  
ERN: 13792552

TO: ERIC E. GOFNUNG CHIROPRACTIC  
CORPORATION  
6221 WILSHIRE BLVD., SUITE 604  
LOS ANGELES, 90048  
Tel 323-933-2444  
Scheduling@Gofnung.com

CC: OD LEGAL  
355 S. GRAND AVE STE 1400  
LOS ANGELES CA 90071

SIBTF  
1750 Howe Avenue, Suite 370  
Sacramento, CA 95825-3367  
Tel 916 928 4601/ fax 916 928 4705

RE: SANDRA SEERAM vs JP MORGAN CHASE  
WCAB: ADJ12217188 (DOI: 05/17/2018 - 05/18/2019)  
SIBTF: SIF12217188

DATE: 6/20/2022

## Attestation Pursuant to Cal Code Regs., Title 8, § 9793(n)

I, Natalia Foley, hereby declare:

I am licensed to practice before all the courts in the state of California.

I am the attorney for Workers Defenders Law Group and attorney of record for the above applicant.

Pursuant to Cal Code Regs., Title 8, § 9793(n), I declare that the provider of the documents has complied with the provision of Labor Code §4062.3 before providing the documents to the physician.

I declare that the total page count of the documents provide to the physician is 6263. Total page count is based on the documents described in the attached list of the evidence.

We reserve our right to amend our exhibits upon further discovery in which case you might be requested to provide your supplemental report to address newly discovered medical evidence.

I declare under penalty of perjury under the laws of the States of California that the foregoing is true and correct to the best of my knowledge.

Executed 6/20/2022, at Anaheim, CA

By Natalia Foley, Esq ( SBN 295923)  
attorney for Applicant

List of Exhibits

**SANDRA SEERAM vs JP MORGAN CHASE**

ADJ12217188 (DOI: 05/17/2018 - 05/18/2019)

SIF12217188

DOB: 11/19/1968

**List of exhibits:**

|                  |  |                             |                |
|------------------|--|-----------------------------|----------------|
| Ex 01            | Deposition transcript Vol I                                | June 26, 2020               | 105            |
| Ex 02            | Deposition transcript Vol II                               | July 24, 2020               | 31             |
| Ex 03            | Notice of Approved Loss                                    | May 29, 2019                | 1              |
| Ex 04            | Kaiser Medical Files                                       |                             | 5454           |
| <del>Ex 05</del> | <del>PQME Dr Spenser supplemental report</del>             | <del>March 11, 2021</del>   | <del>72</del>  |
| <del>Ex 06</del> | <del>Transcript of Cross-Examination of Dr. Spenser</del>  | <del>October 19, 2020</del> | <del>51</del>  |
| <del>Ex 07</del> | <del>Psych PTP Dr. Curtis P&amp;S report</del>             | <del>March 31, 2020</del>   | <del>30</del>  |
| Ex 08            | Applicant Personnel File                                   |                             | 204            |
| <del>Ex 09</del> | <del>PQME Dr. Joanne Halbrecht MD report</del>             | <del>2020-12-04</del>       | <del>61</del>  |
| <del>Ex 10</del> | <del>PTP Dr. Iseke MMI report</del>                        | <del>January 08, 2020</del> | <del>11</del>  |
| <del>Ex 11</del> | <del>PQME Dr. Spenser P&amp;S report</del>                 | <del>August 28, 2020</del>  | <del>67</del>  |
| <del>Ex 12</del> | <del>DEU consultative rating Per Dr Iseke and Curtis</del> | <del>05/13/2021</del>       | <del>2</del>   |
| <del>Ex 13</del> | <del>Psych Eval by Gul Ebrahim MD</del>                    | <del>2021-05-21</del>       | <del>5</del>   |
| <del>ex 14</del> | <del>Psych Report by PTP Dr. Curtis</del>                  | <del>2019-12-19</del>       | <del>7</del>   |
| <del>ex 15</del> | <del>Psych Report by PTP Dr. Curtis</del>                  | <del>2019-10-07</del>       | <del>5</del>   |
| <del>ex 16</del> | <del>Psych Report by PTP Dr. Curtis</del>                  | <del>2019-07-19</del>       | <del>3</del>   |
| <del>ex 17</del> | <del>Report by PTP Dr Daldalyan MD</del>                   | <del>2021-12-17</del>       | <del>13</del>  |
| <del>Ex 18</del> | <del>DEU rating Dr Joanne Halbert Qme</del>                | <del>2022-04-30</del>       | <del>2</del>   |
| <del>Ex 19</del> | <del>DEU rating for dr Spencer</del>                       | <del>2022-04-30</del>       | <del>1</del>   |
| <del>Ex 20</del> | <del>PQME P&amp;S eval Dr Stewart Lonky MD</del>           | <del>2022-04-26</del>       | <del>138</del> |
| TOTAL:           |  |                             | 6263           |

All medical can be downloaded here:

<https://nataliafoleylaw.com/01%20-%20SANDRA%20SEERAM.html>